OCT guided Rotablation in bifurcation lesions

Caress Sapporo

Hokko Memorial Hospital

Yoichi Nozaki, MD

IVUS and OCT/OFDI

Lipidic plaque

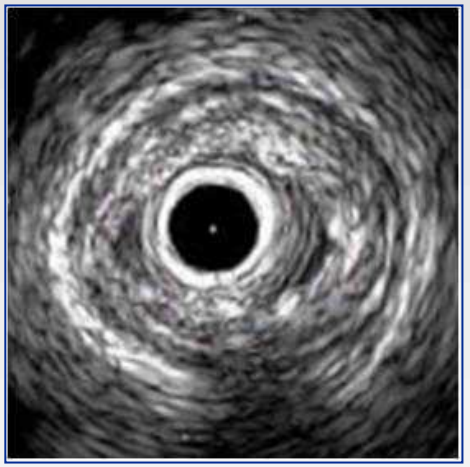

Fibrous plaque

Calcified plaque

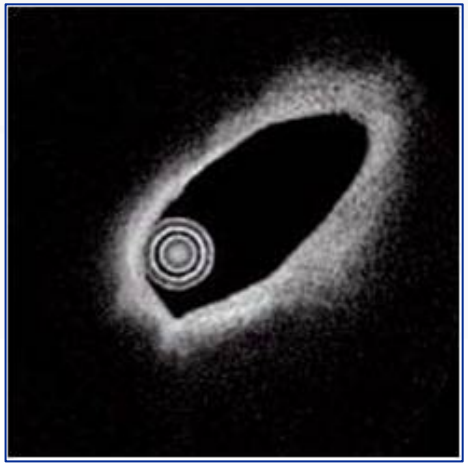

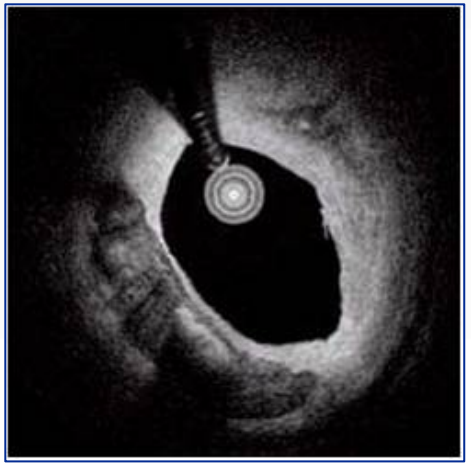

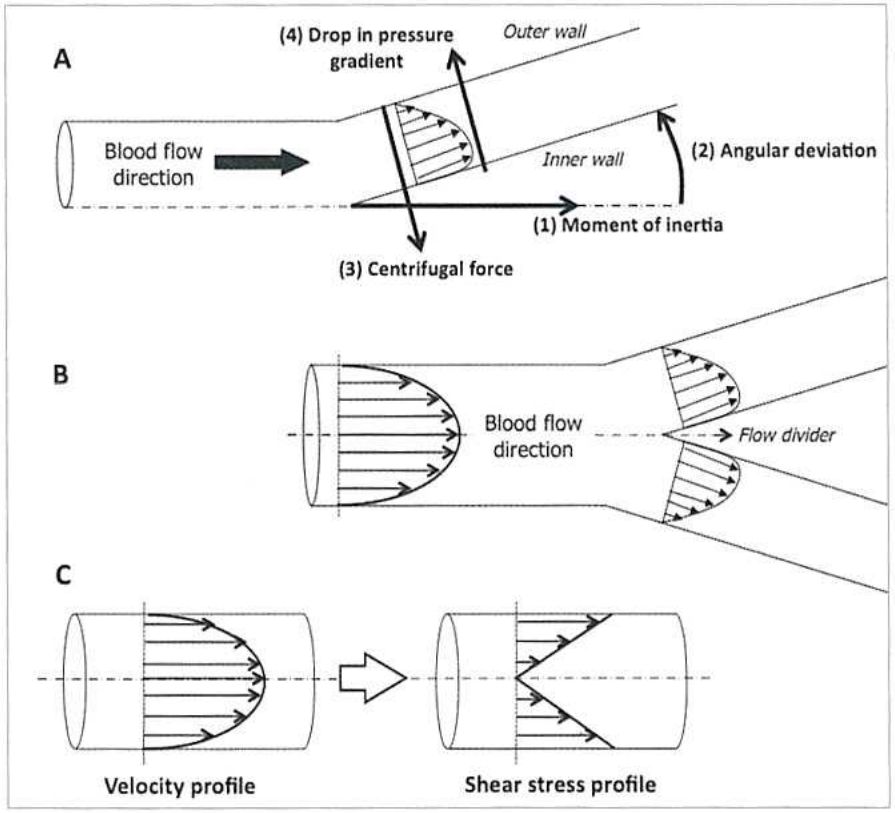

Figure 3. Schematic analysis of bifurcation impact on fluid dynamics. A) Laminar flow in an artery induces a force of inertia (1) in the direction of flow; a sudden change in direction characterised by an angular deviation (2) induces a centrifugal force (3) which creates a pressure gradient at the exit from the change in direction. B) Description of fluid dynamics changes from symmetric laminar flow before the bifurcation to asymmetric flow gradients after division of the flow. C) The flow velocity profile is associated with a shear stress profile, corresponding to the derivative of the velocities from their radial position.

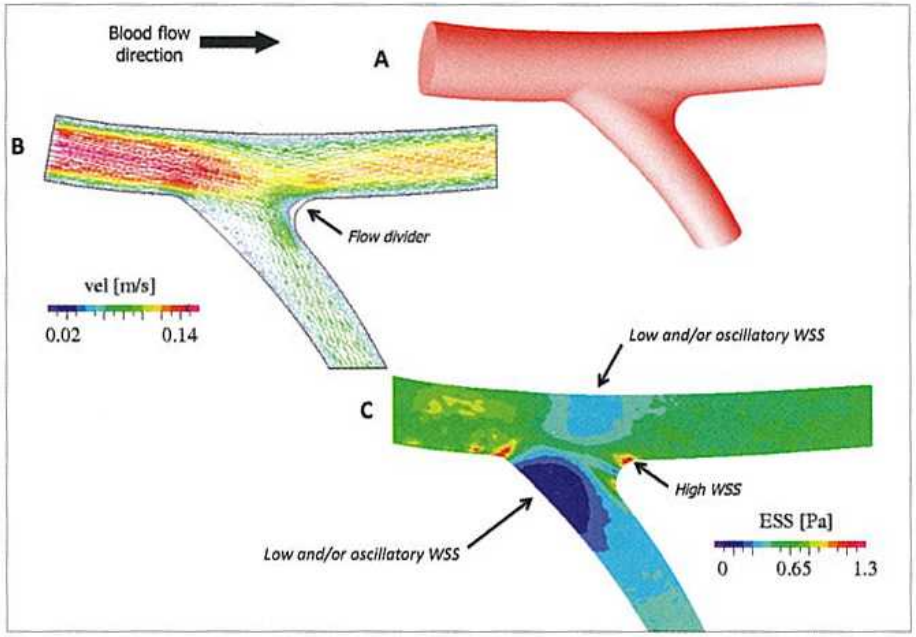

Figure 4. Numeric simulation in coronary bifurcations. A) The coronary bifurcation model respects a fractal geometry. B) Map of velocity profile, showing the preferential route towards the flow divider induced by the force of inertia. C) Map of wall shear stress (WSS) showing two contrasting regions at the flow divider where WSS is low, regions where flow is very slow and/or oscillatory.

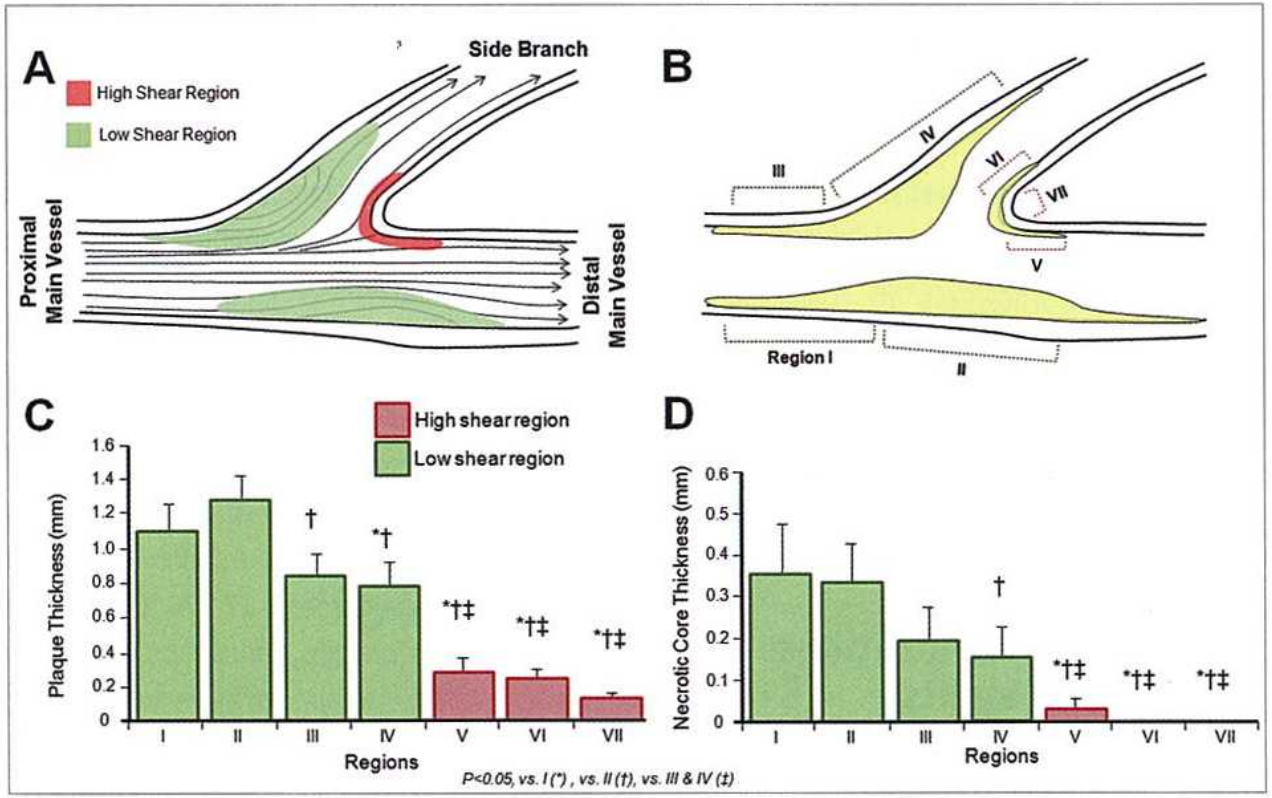

Figure 1. Morphometric analysis of native coronary bifurcations. (A) Schematic diagram illustrating flow behaviour within a coronary branch with low shear regions observed in the lateral walls and high shear regions observed at the carinal region. (B) For non-stented atherosclerotic lesions, sections were assessed based on the longitudinal location; Region I - Proximal main vessel, Region II - Distal main vessel on the lateral wall, Region III - Proximal main vessel on the side branch, Region IV - Distal side branch on the lateral wall, Region V - Distal main vessel on the flow divider side, Region VI - Distal side branch on the flow divider side, and Region VII - Carinal region. (C) Plaque thickness was greater in regions of low shear as compared to high shear. (D) Similarly, necrotic core thickness was significantly greater in low shear regions as compared to high shear. Note the absent of necrotic core at the carinal region (VII).

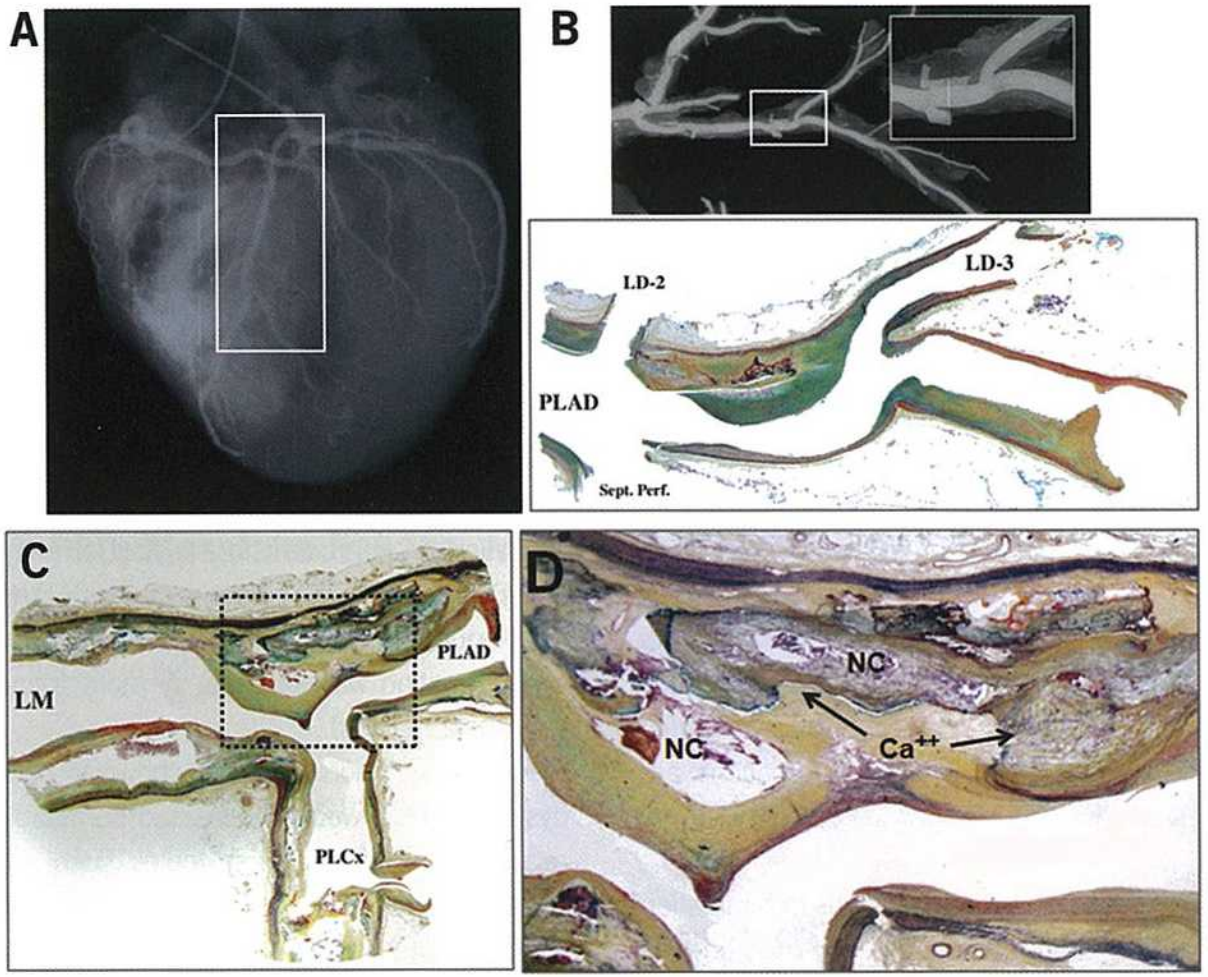

Figure 2. Representative histologic images of coronary plaque in bifurcation lesion. (A-B). Photograph of an angiogram following high contrast x-ray of the bifurcation lesion (LAD / left diagonal). Note presence of atherosclerotic plaques in the lateral wall, while the flow divider regions are spared. (C-D) Longitudinal section taken in the region of LM/PLAD/PLCx bifurcation. Note, severe luminal narrowing proximal to the bifurcation. Necrotic core (NC) accompanied with heavy calcification (Ca++) is observed within the plaque at the low shear (lateral wall) region, whereas the high shear (the carina) has minimal intimal thickening. (LM - Left main, PLAD - proximal left anterior descending coronary artery, PLCx - proximal left circumflex).

LAD CPR （LCX bif）

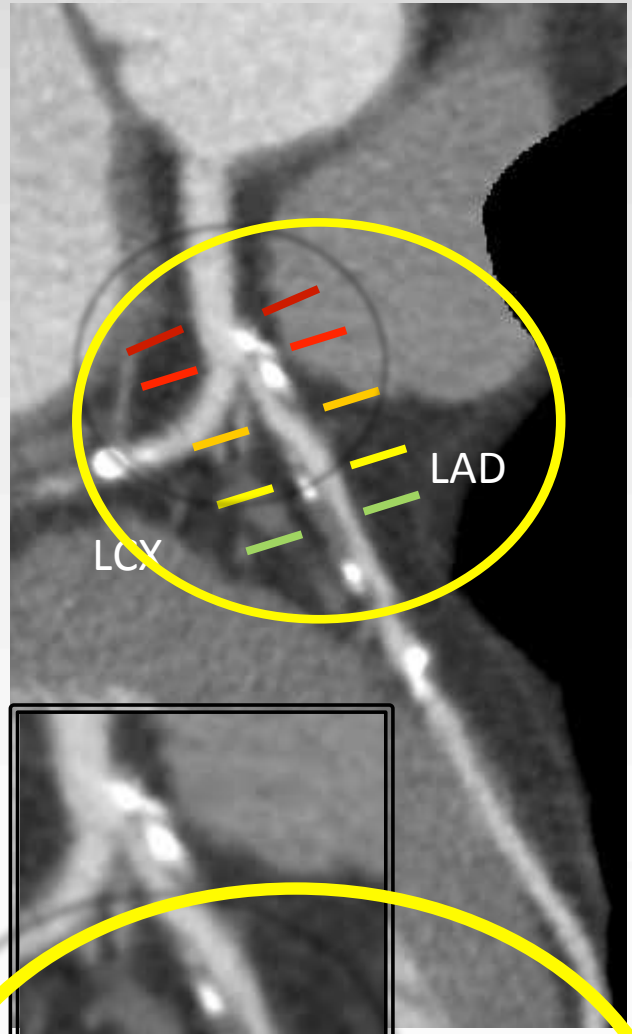

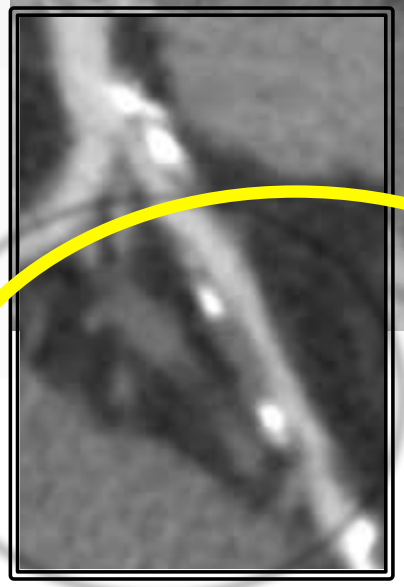

LAD CPR （D1 bif）

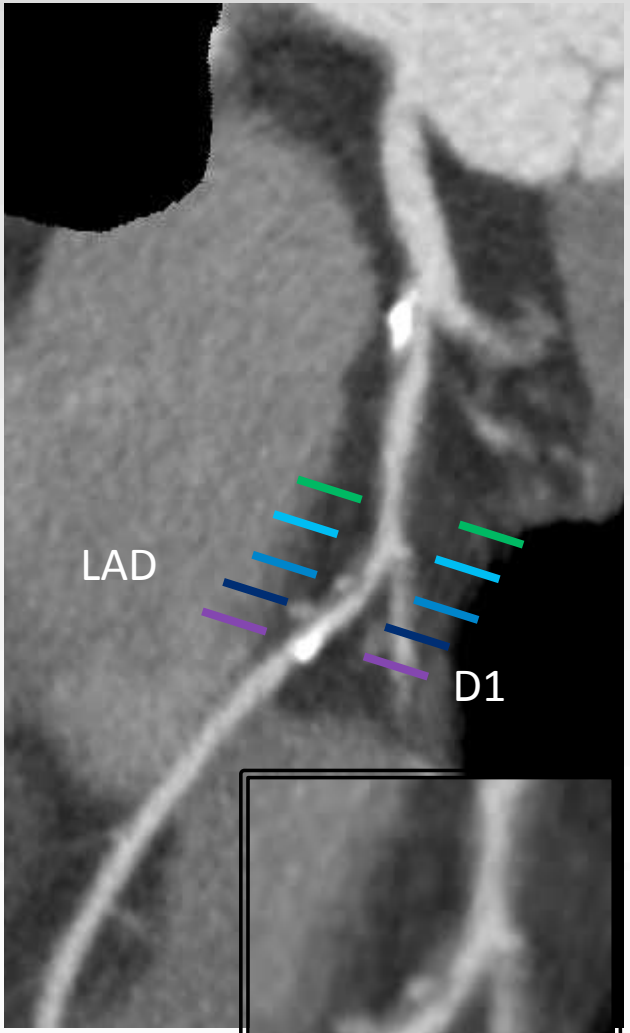

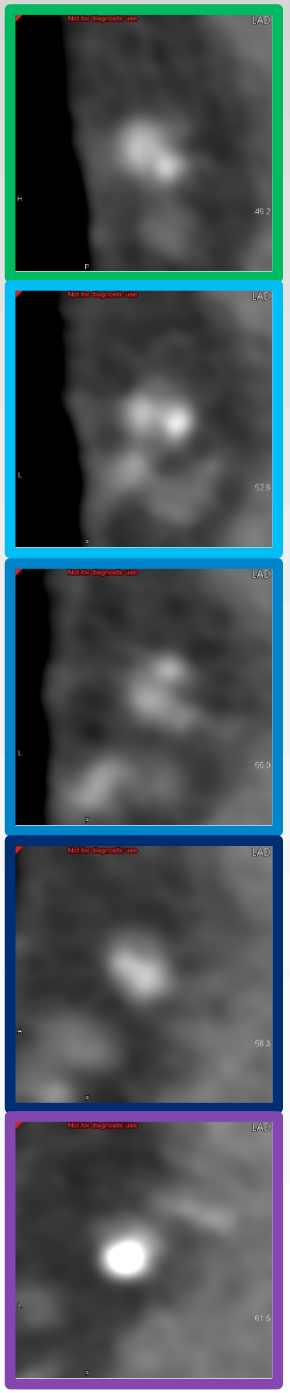

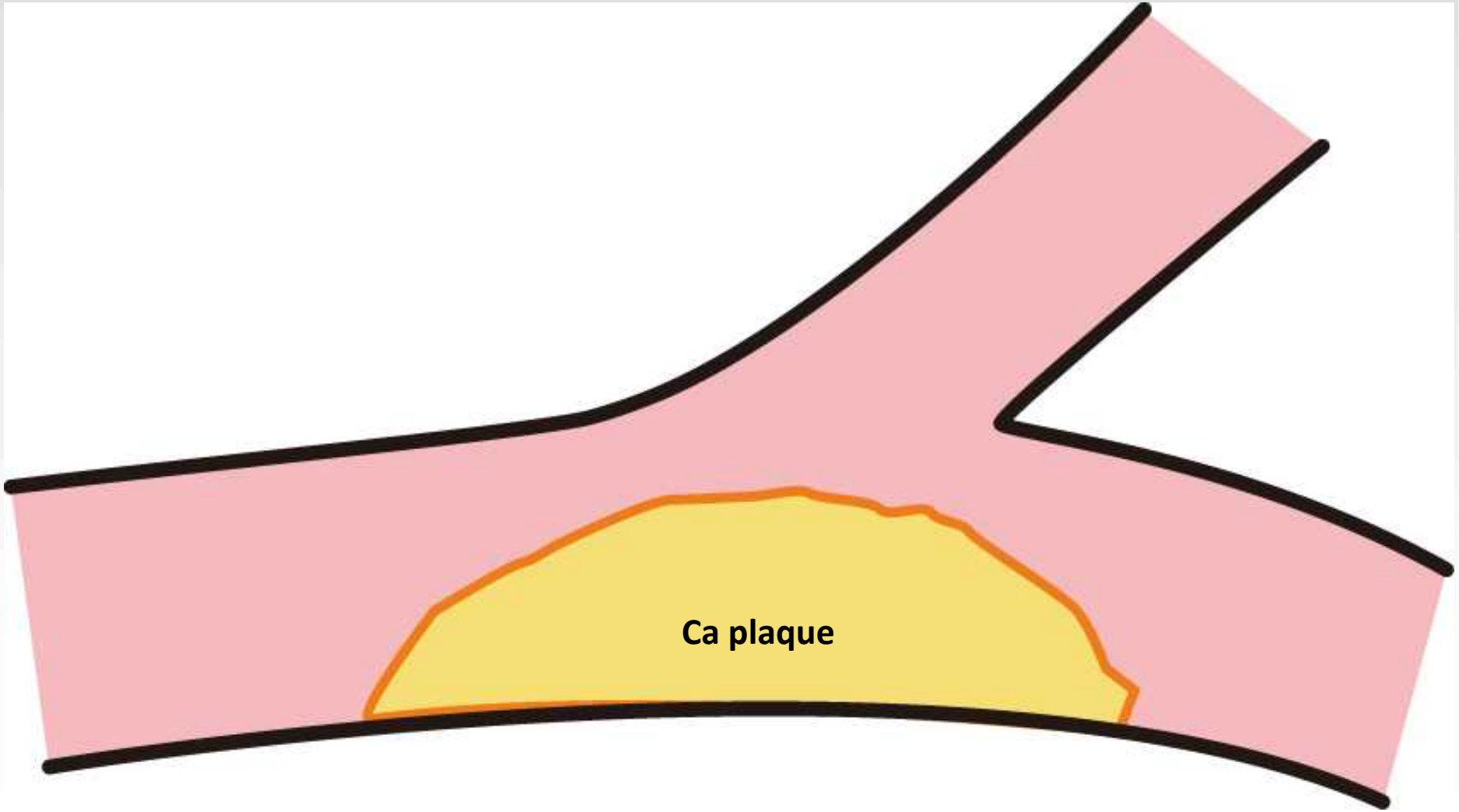
Ca plaque

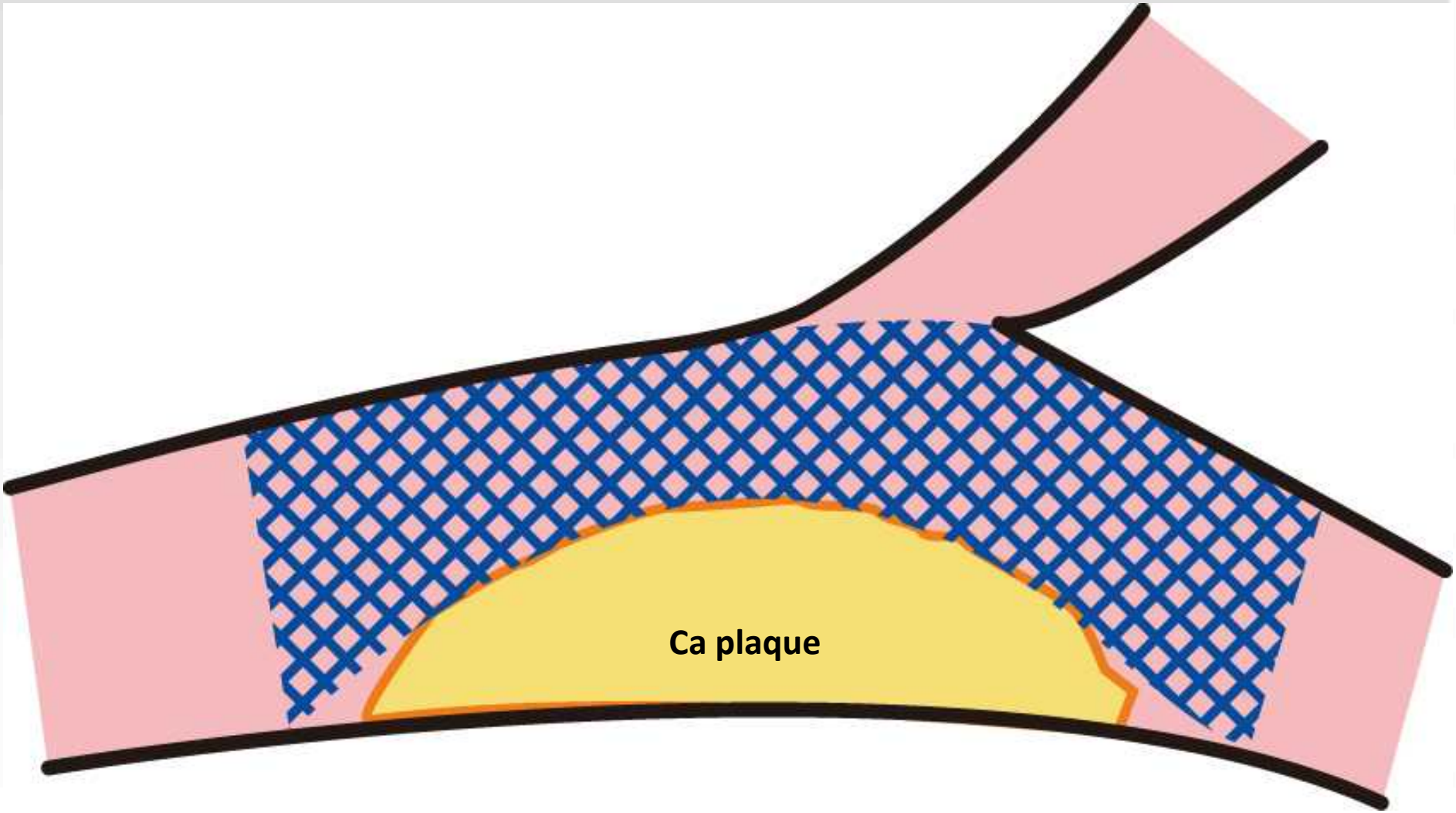
Ca plaque

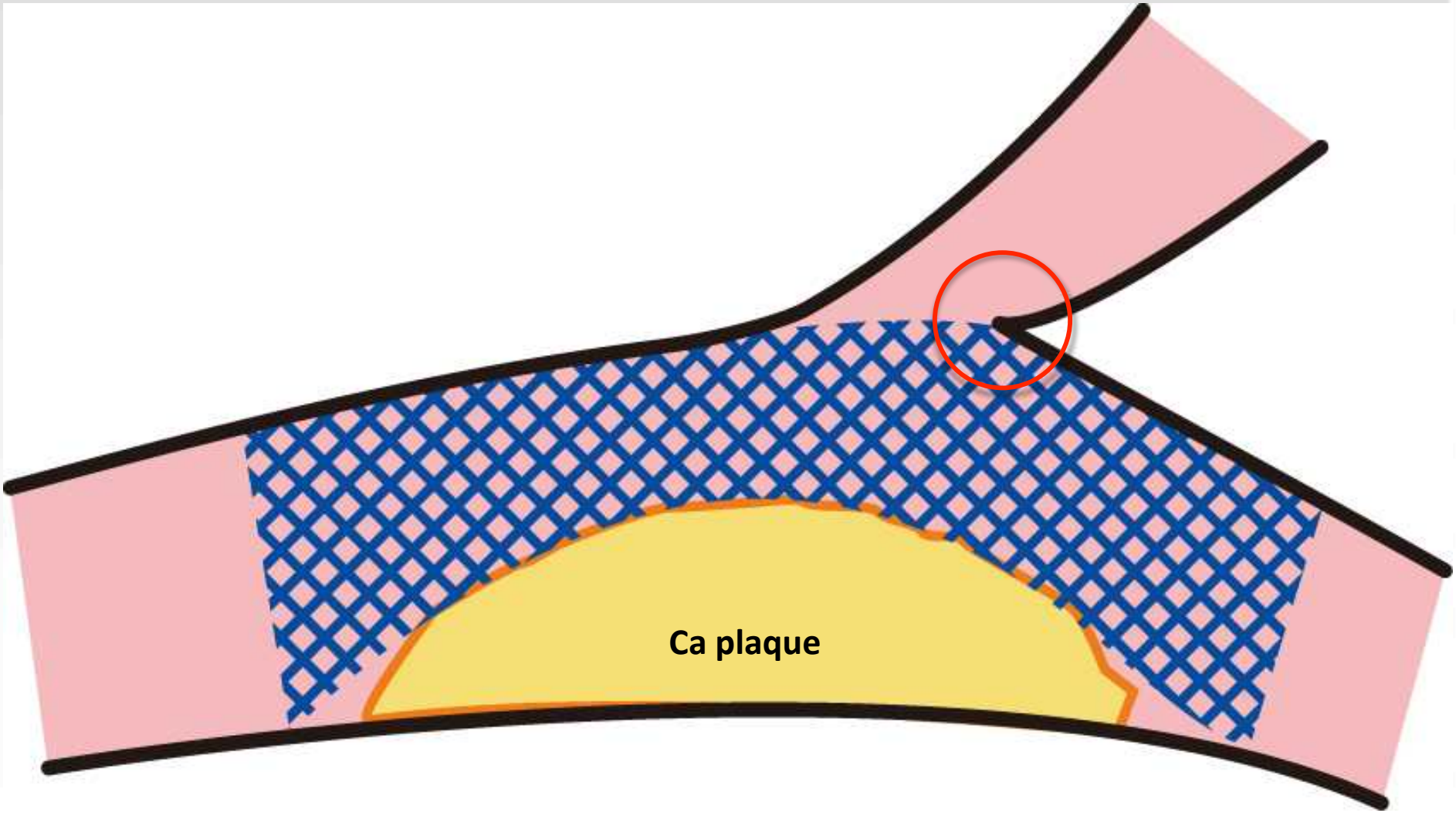
Ca plaque

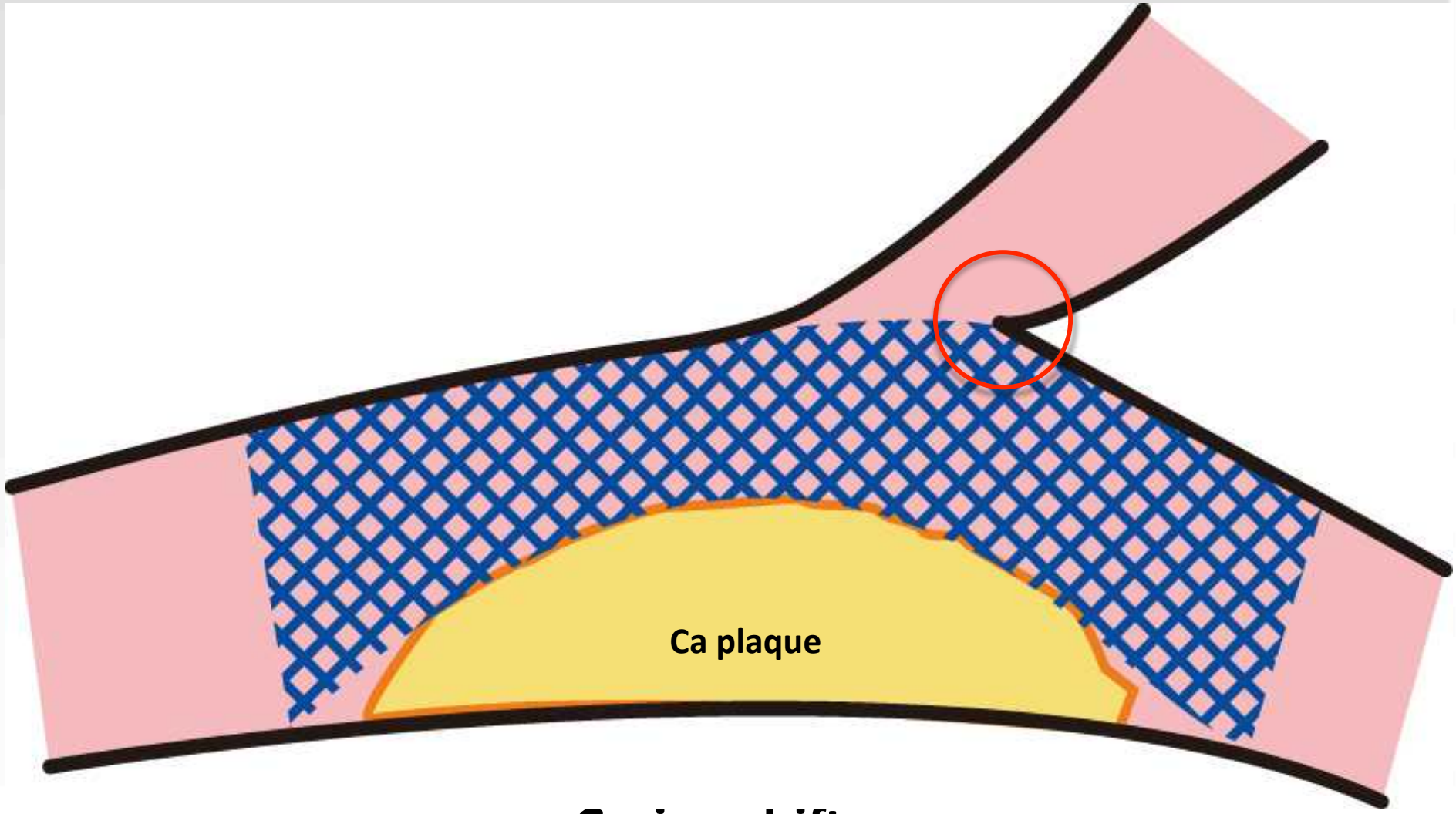

Carina shift

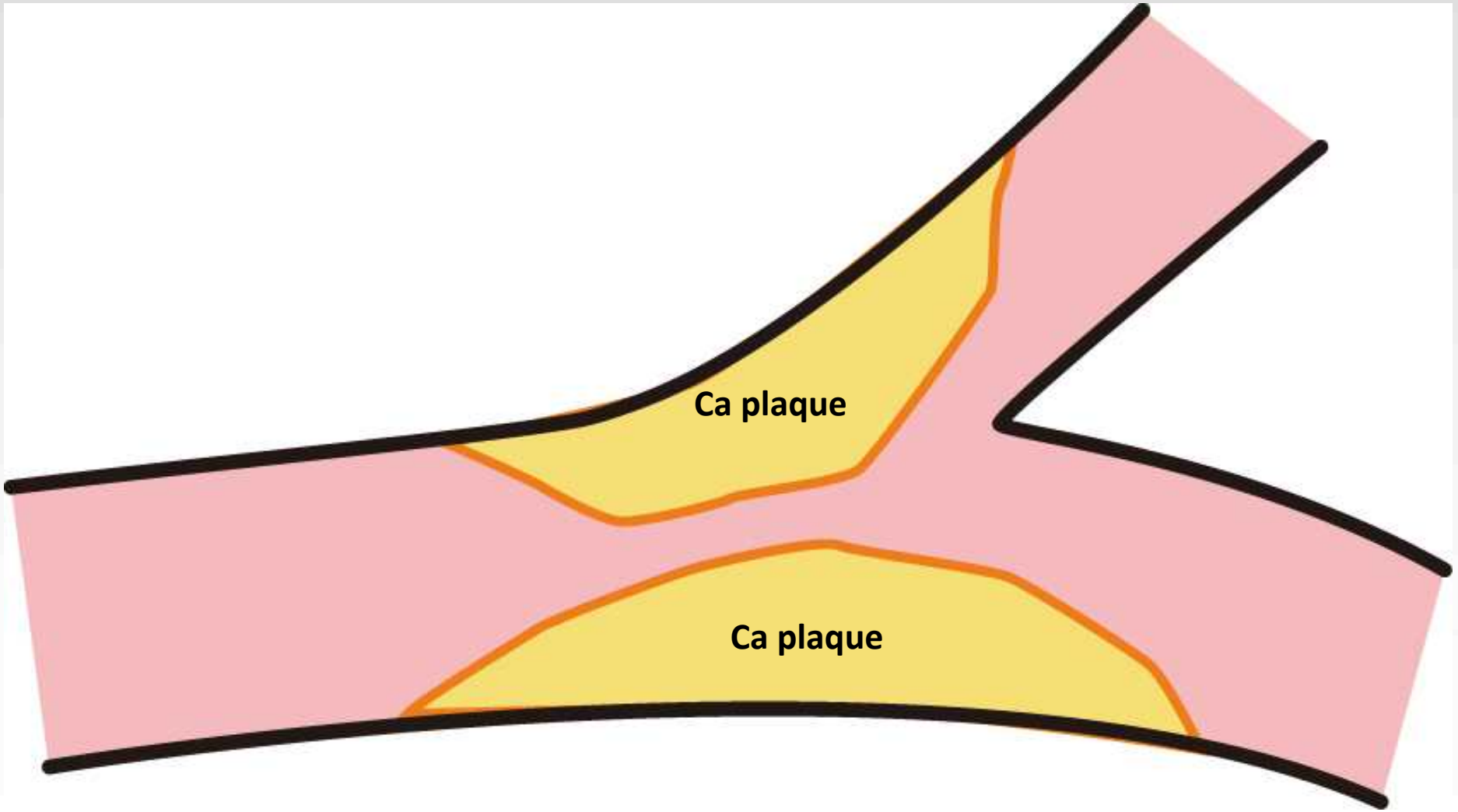
Ca plaque
Ca plaque

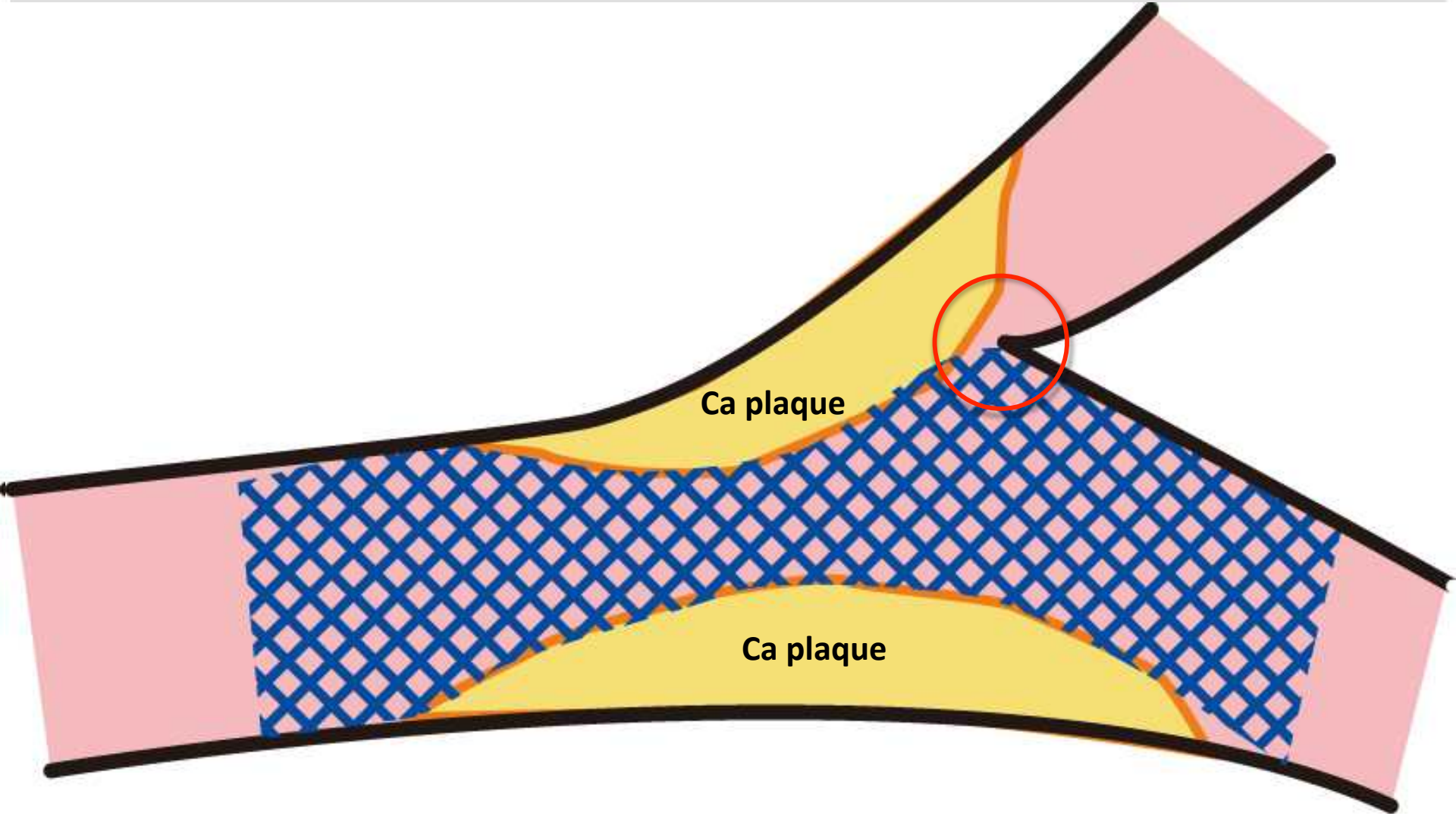
Ca plaque
Ca plaque

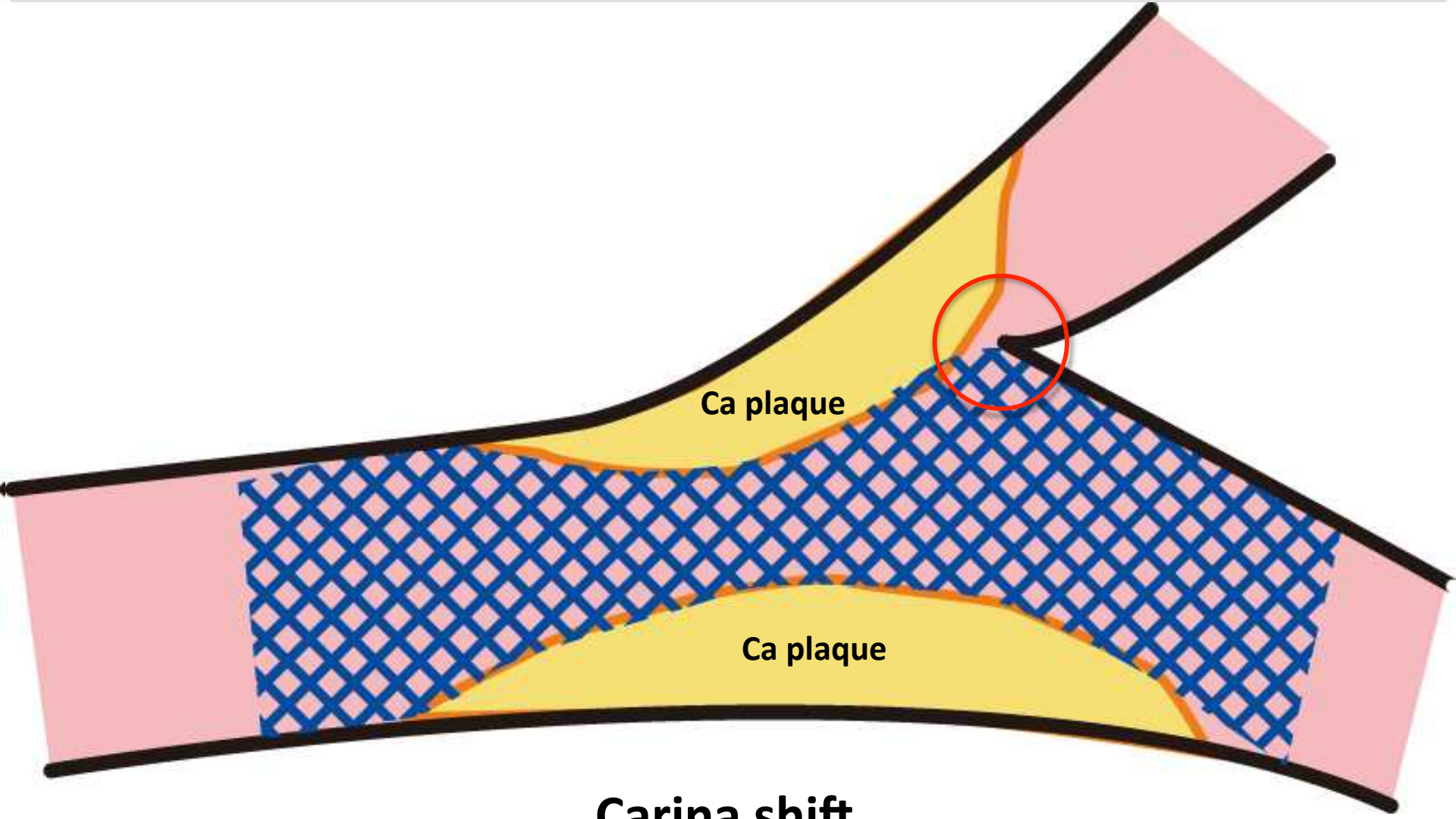

Carina shift

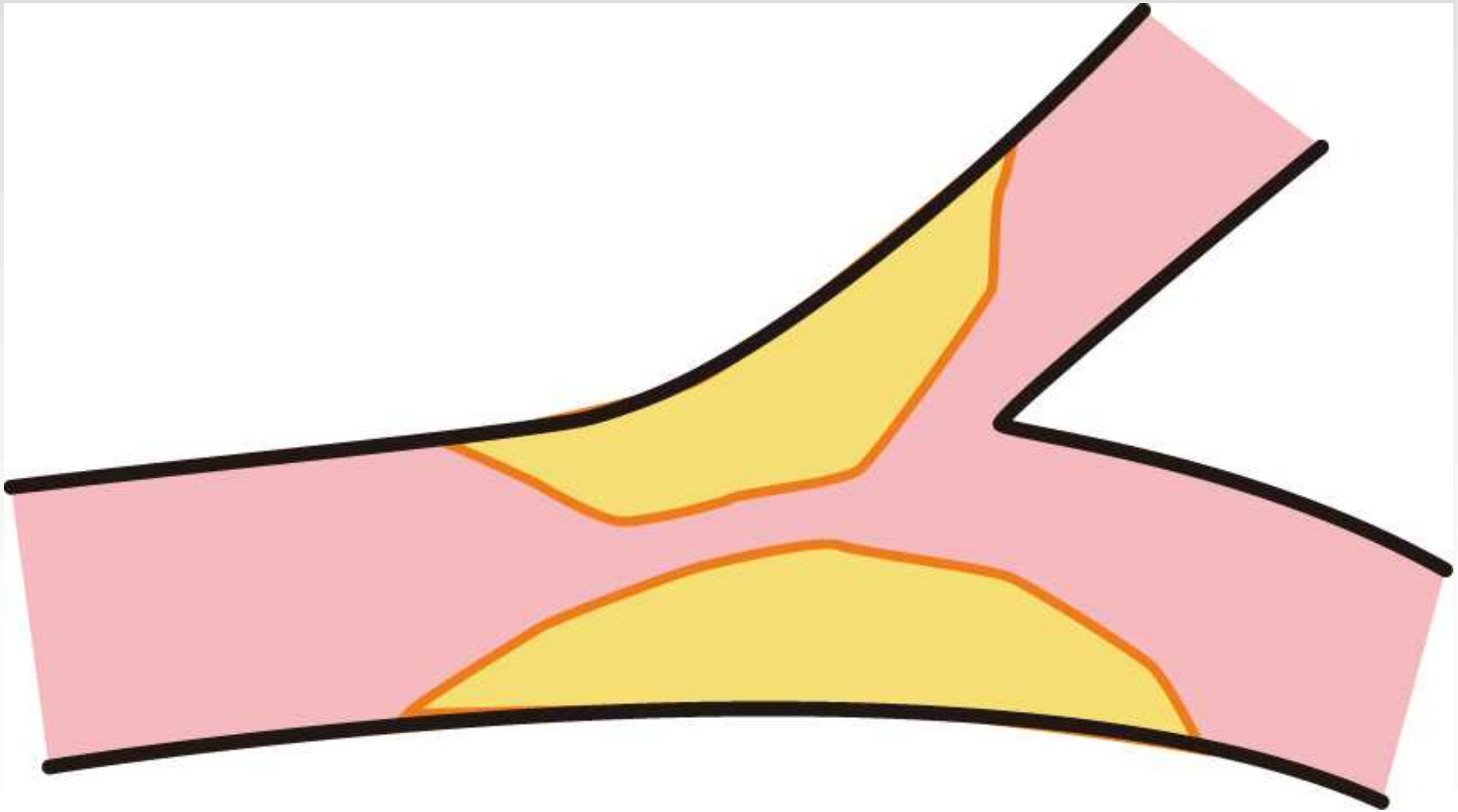

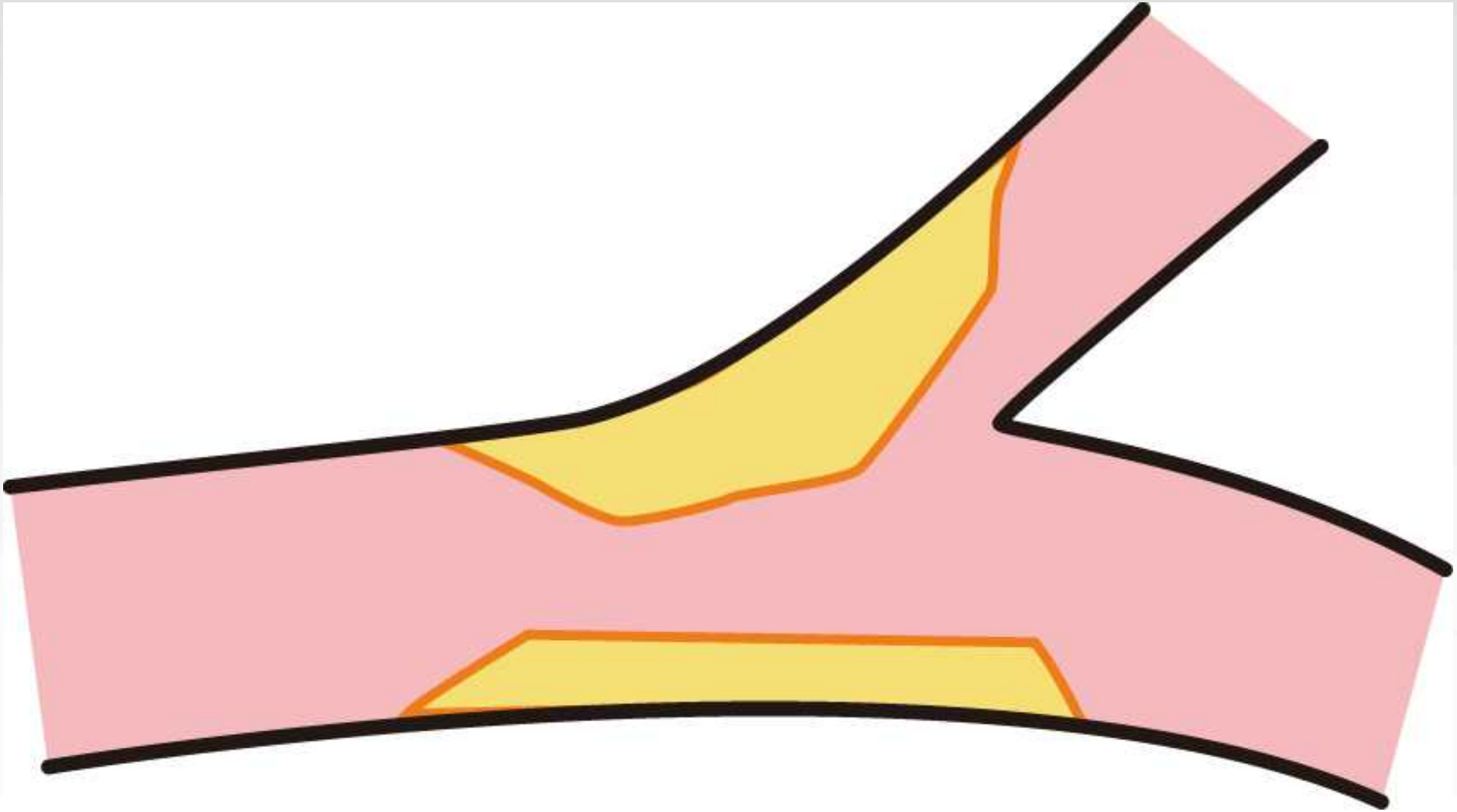

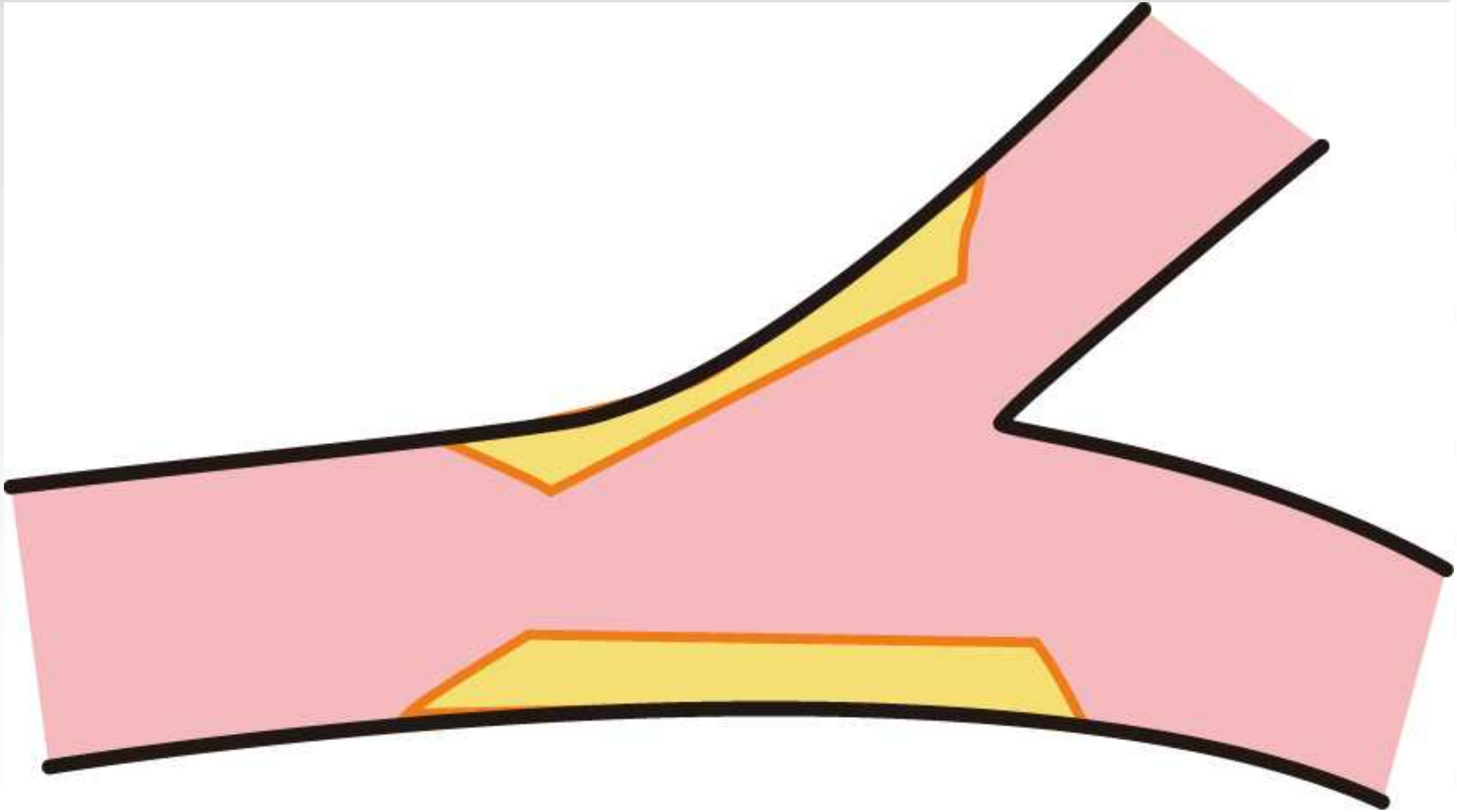

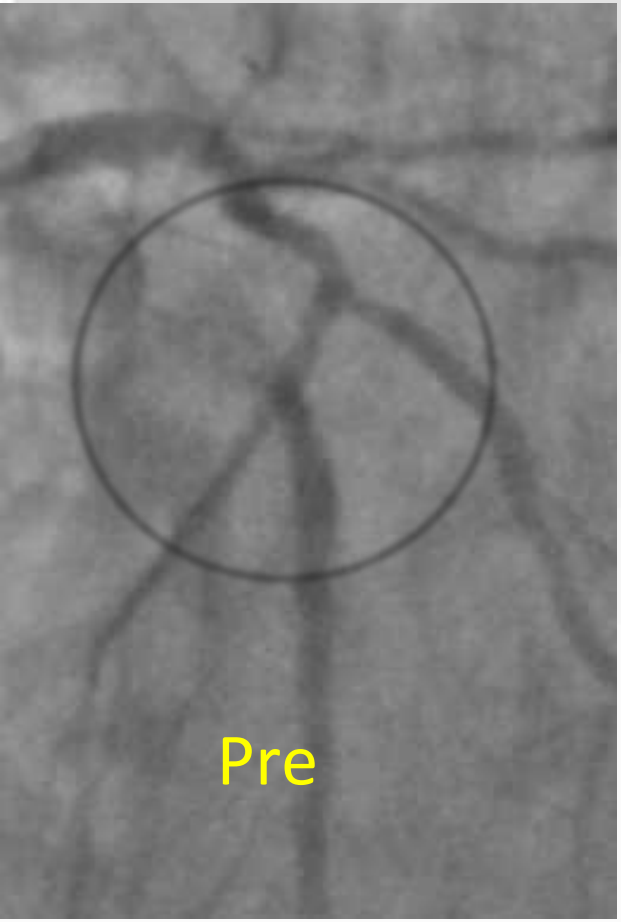
Pre

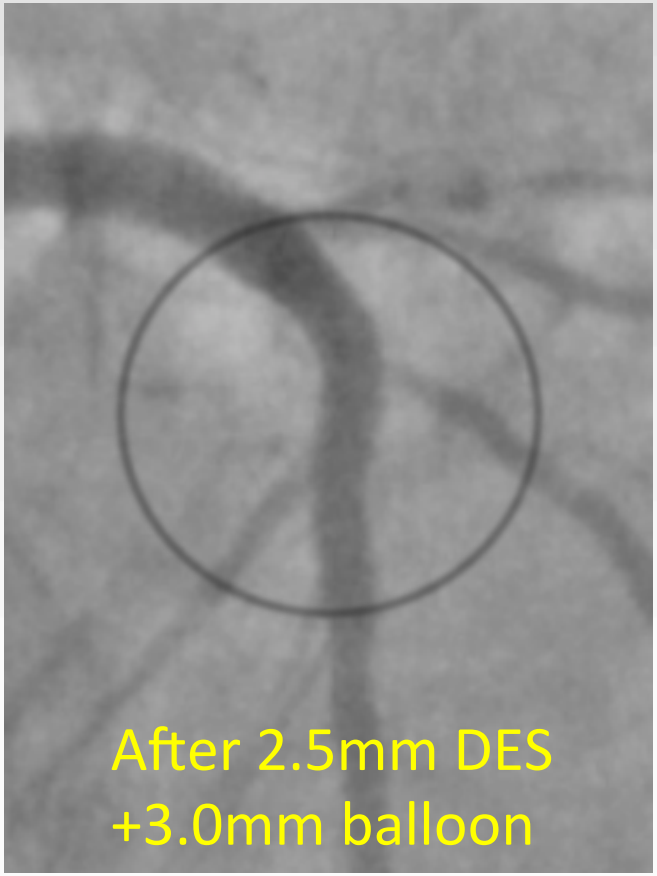
After 2.5mm DES
+3.0mm balloon

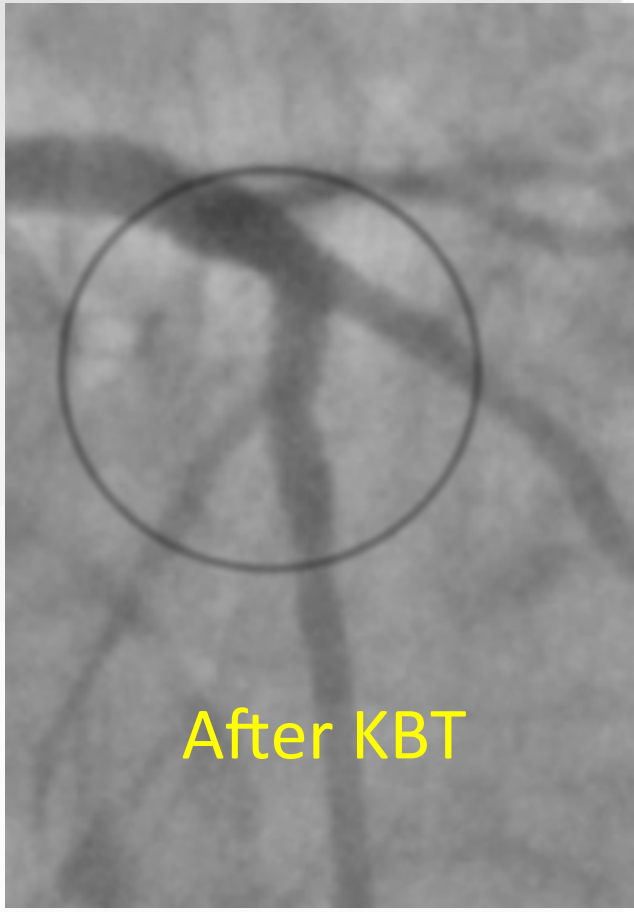
After KBT

OFDI image

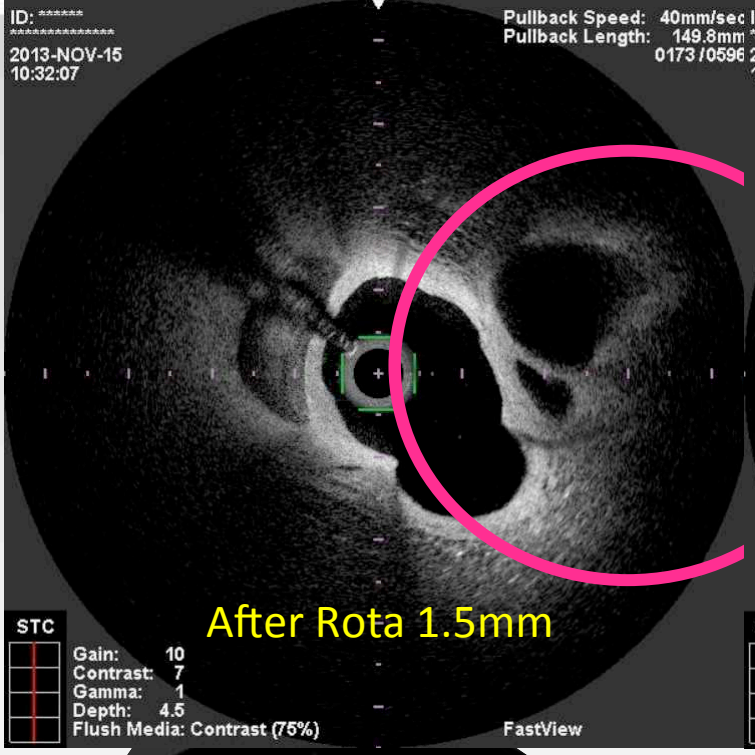

After Rota 1.5mm

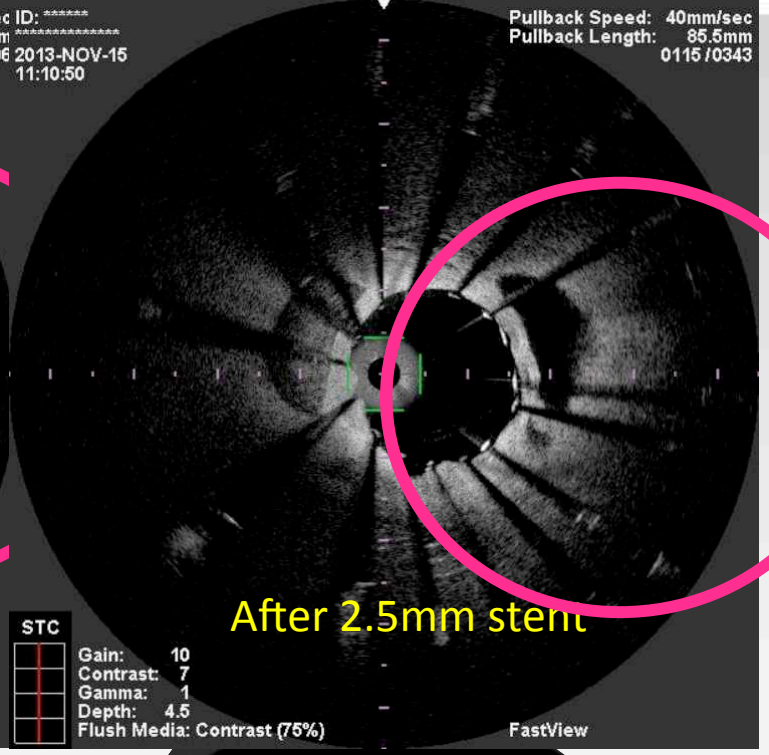

After 2.5mm stent

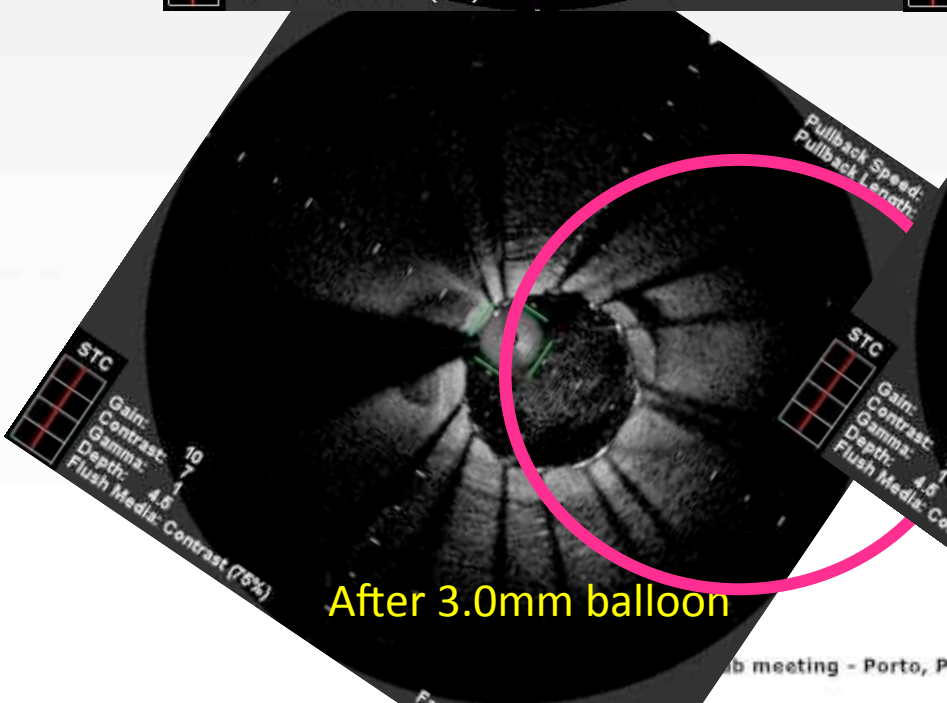

After 3.0mm balloon

After 3.0mm balloon

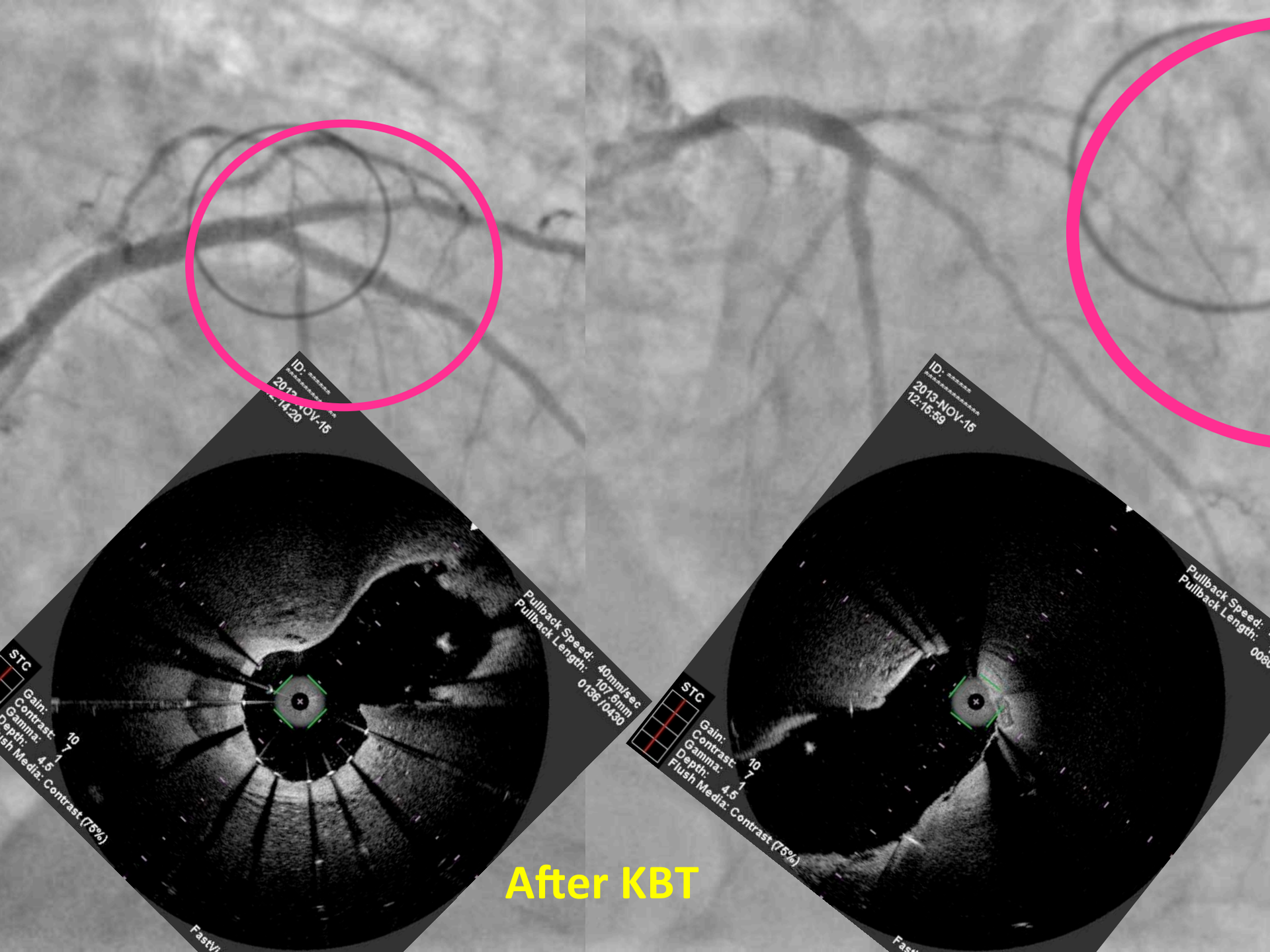
ID:
2013-NOV-15
12:16:59
Pullback Speed:
Pullback Length:
STC
Gain:
Contrast:
Gamma:
Depth:
Flush Media: Contrast (75%)
ID:
2013-NOV-15
Pullback Speed: 40mm/sec
Pullback Length: 107.6mm
0136 /0430
STC
Gain: 10
Contrast: 7
Gamma: 1
Depth: 4.5
Flush Media: Contrast (75%)
After KBT

Rotablator



Figure 1.4 A&B

Microscopy After Treatment

Histologic examination of arteries after treatment with rotational atherectomy reveals a smooth round lumen.

A) Scanning Electron Micrograph

A smooth luminal surface is often created by the diamond-tipped burr of the Rotablator system, as demonstrated by this scanning electronmicrograph.

B) Lumen Cross Section

A histological cross section of a vessel treated with the Rotablator reveals a smooth concentric lumen.

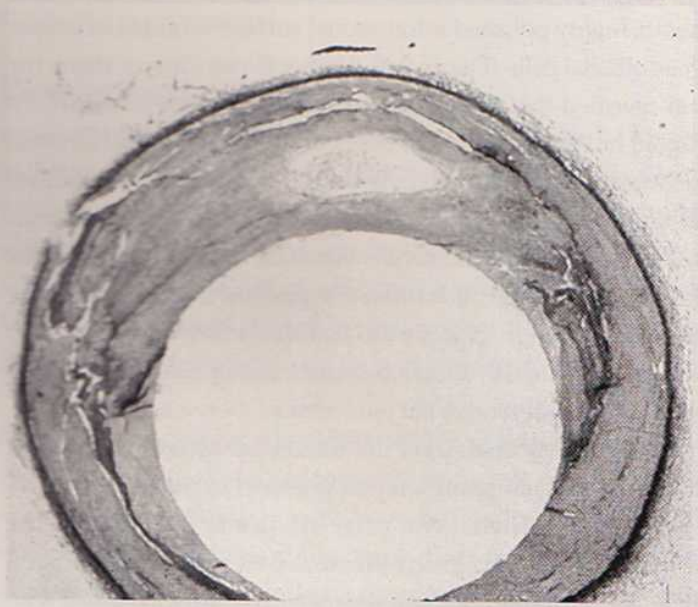

From Mark Reisman Guide to Rotational atherectomy

after ballooning

After rotablator

PTCRA

- minimal vessel stretching and elastic recoil
- elimination of baro-trauma of vessel
- smoothing of inner lumen and improvement of vessel flow
- facilitate to crossability and expansion of stent

Rota Wire

Floppy Type



Extra Support Type

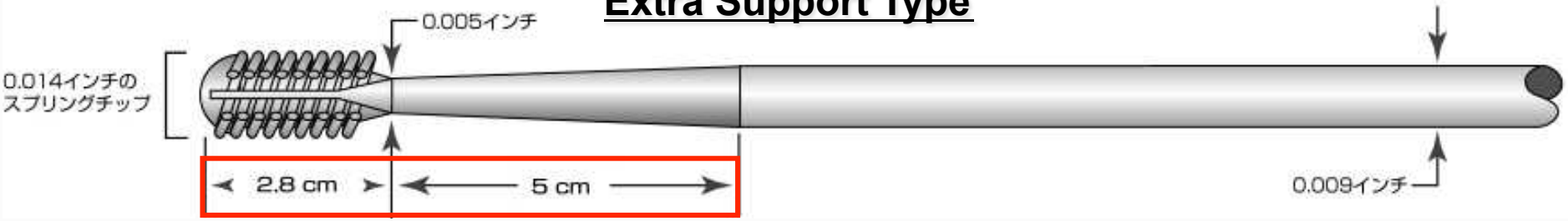

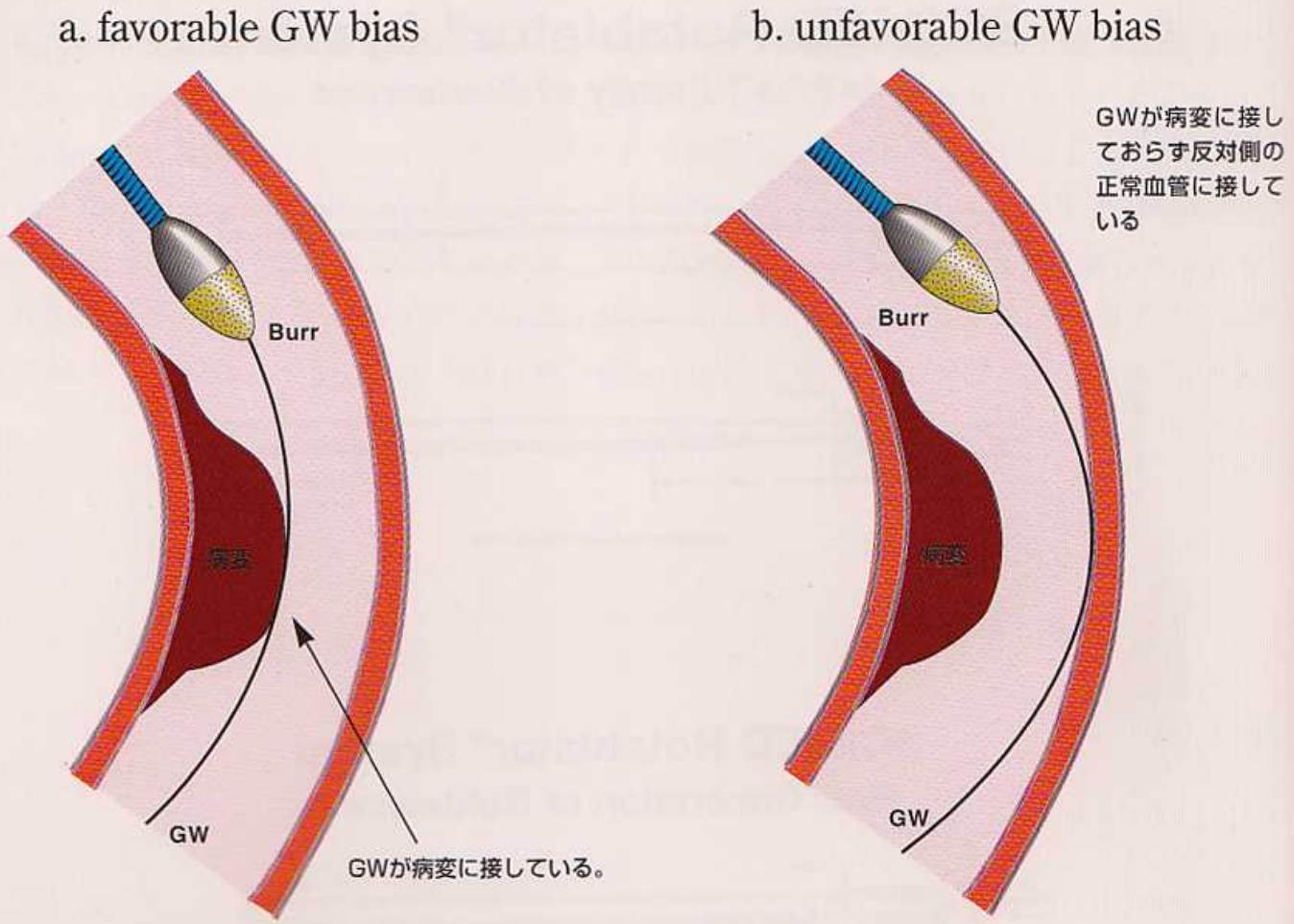

図28　favorable GW biasとunfavorable GW biasの状態

From textbook　Rotablator Illustrated by Kazuo Misumi

case1

症例

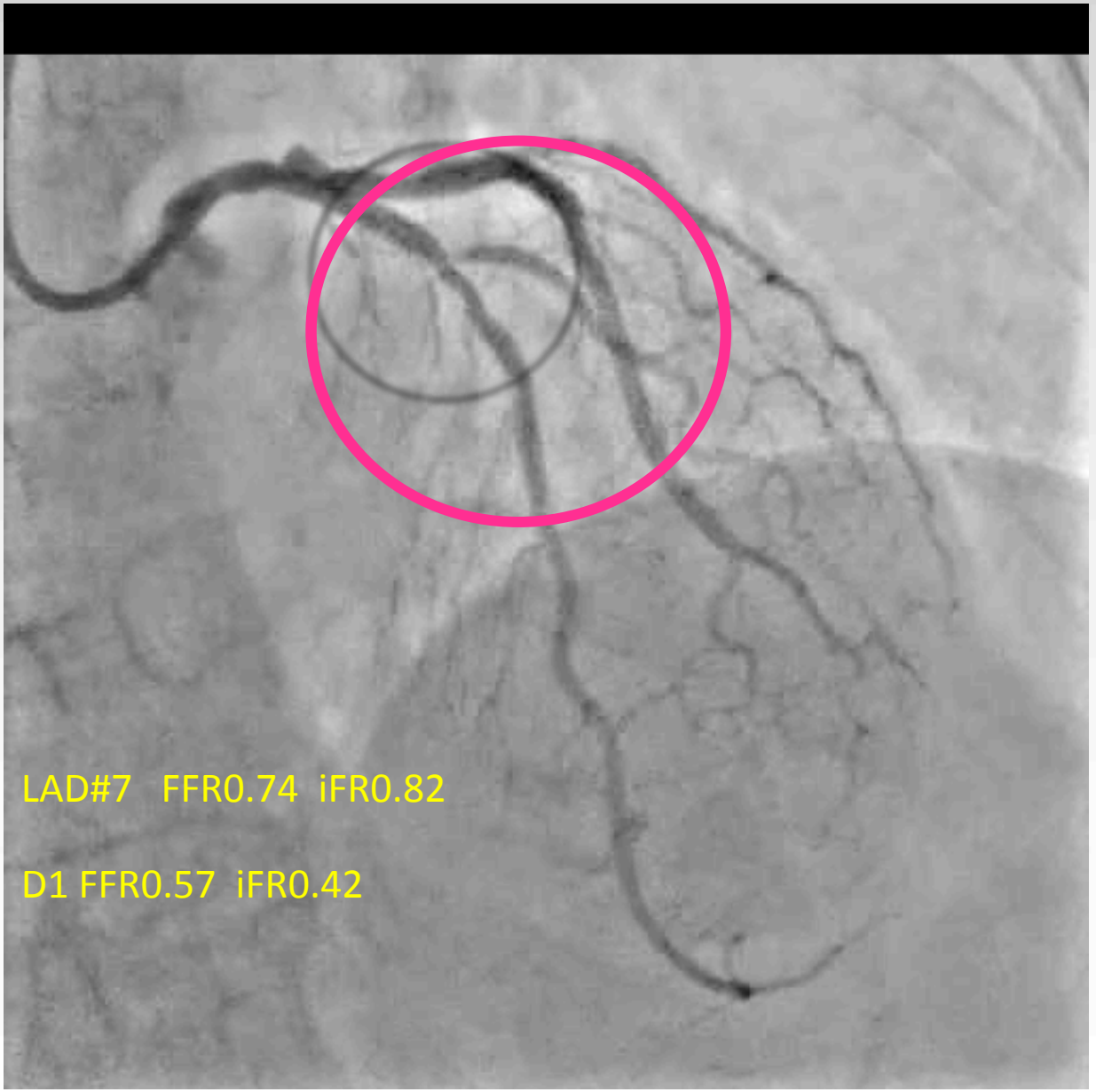

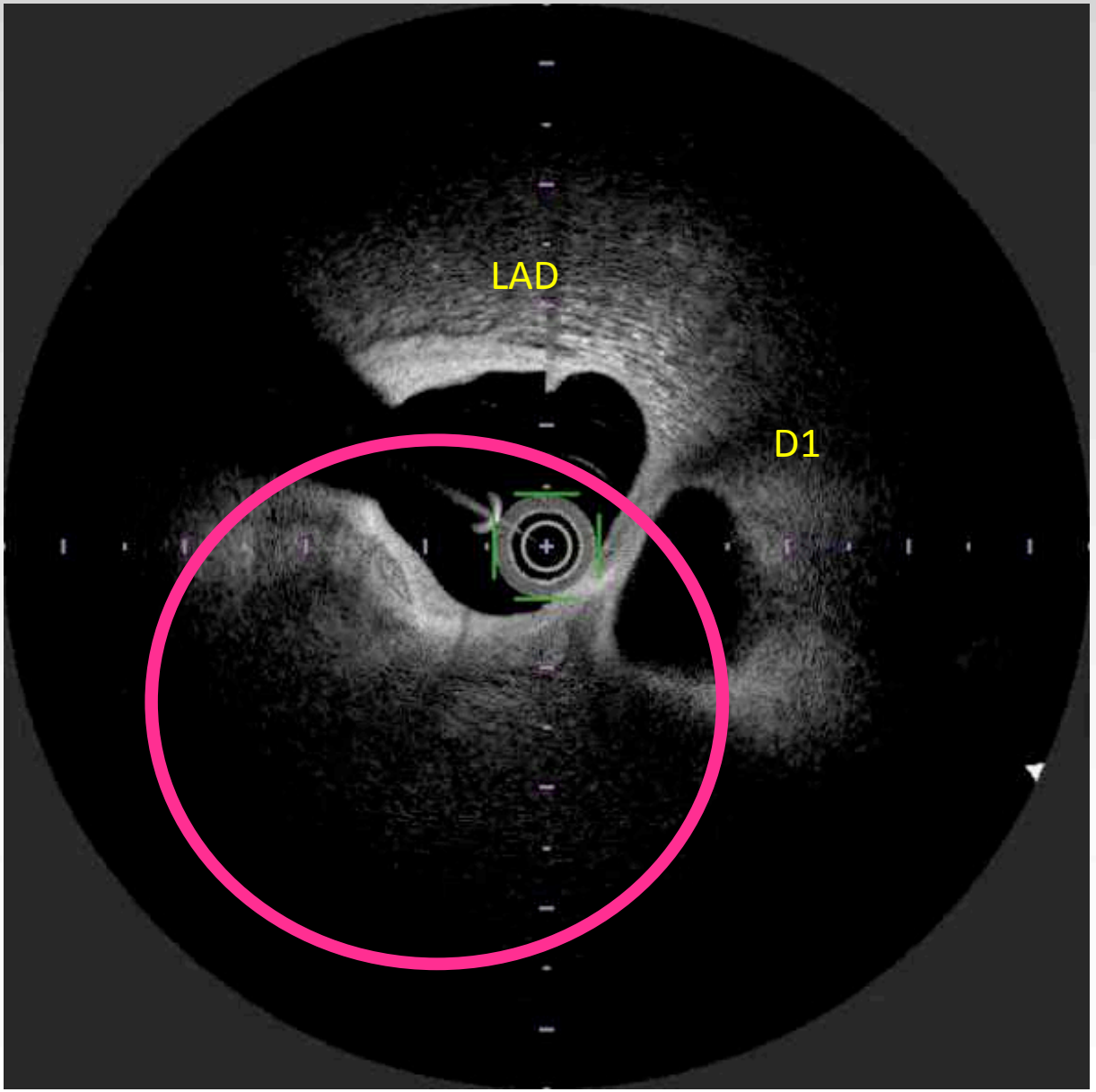

LAD OFDI

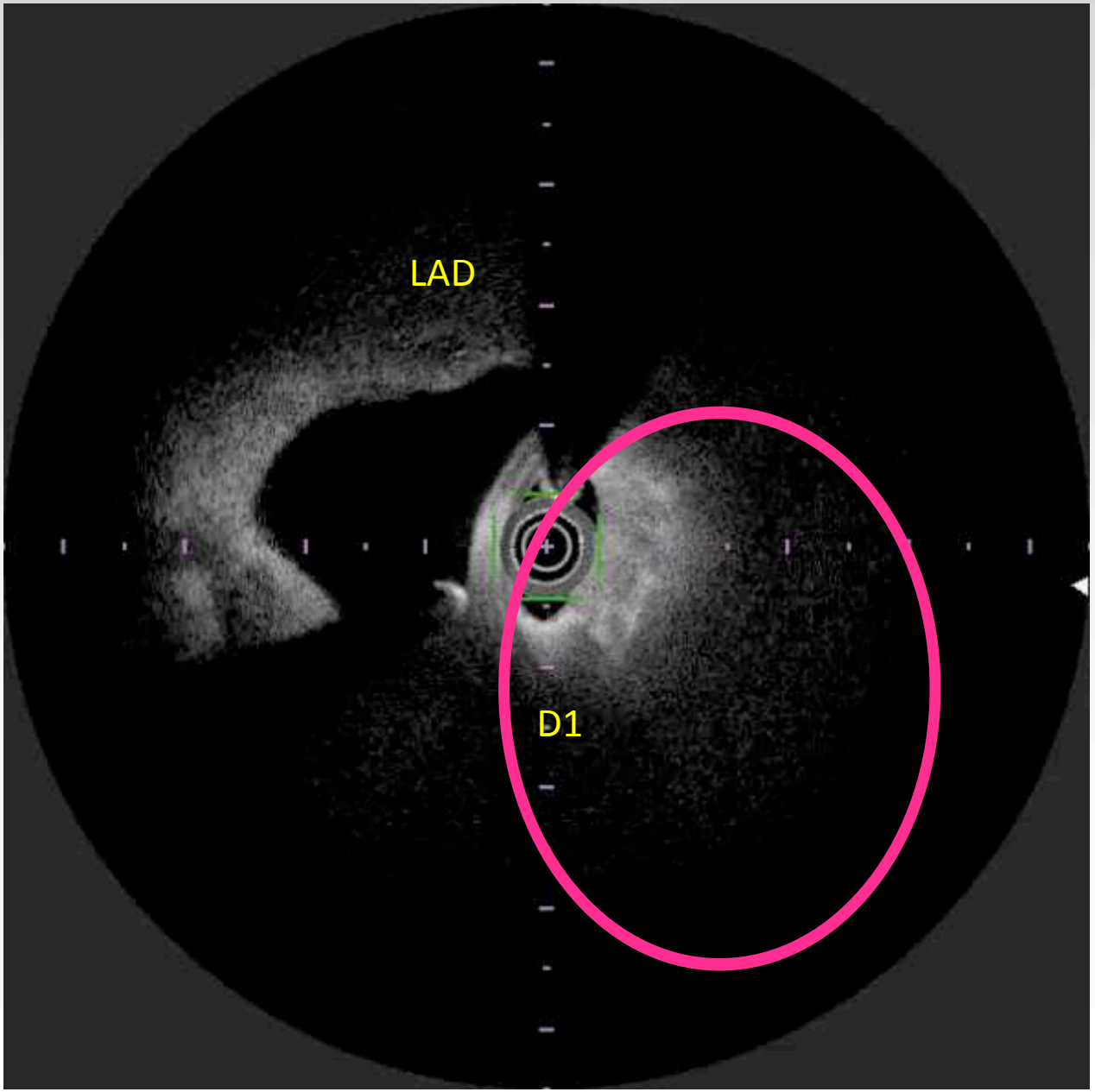

D1 OFDI

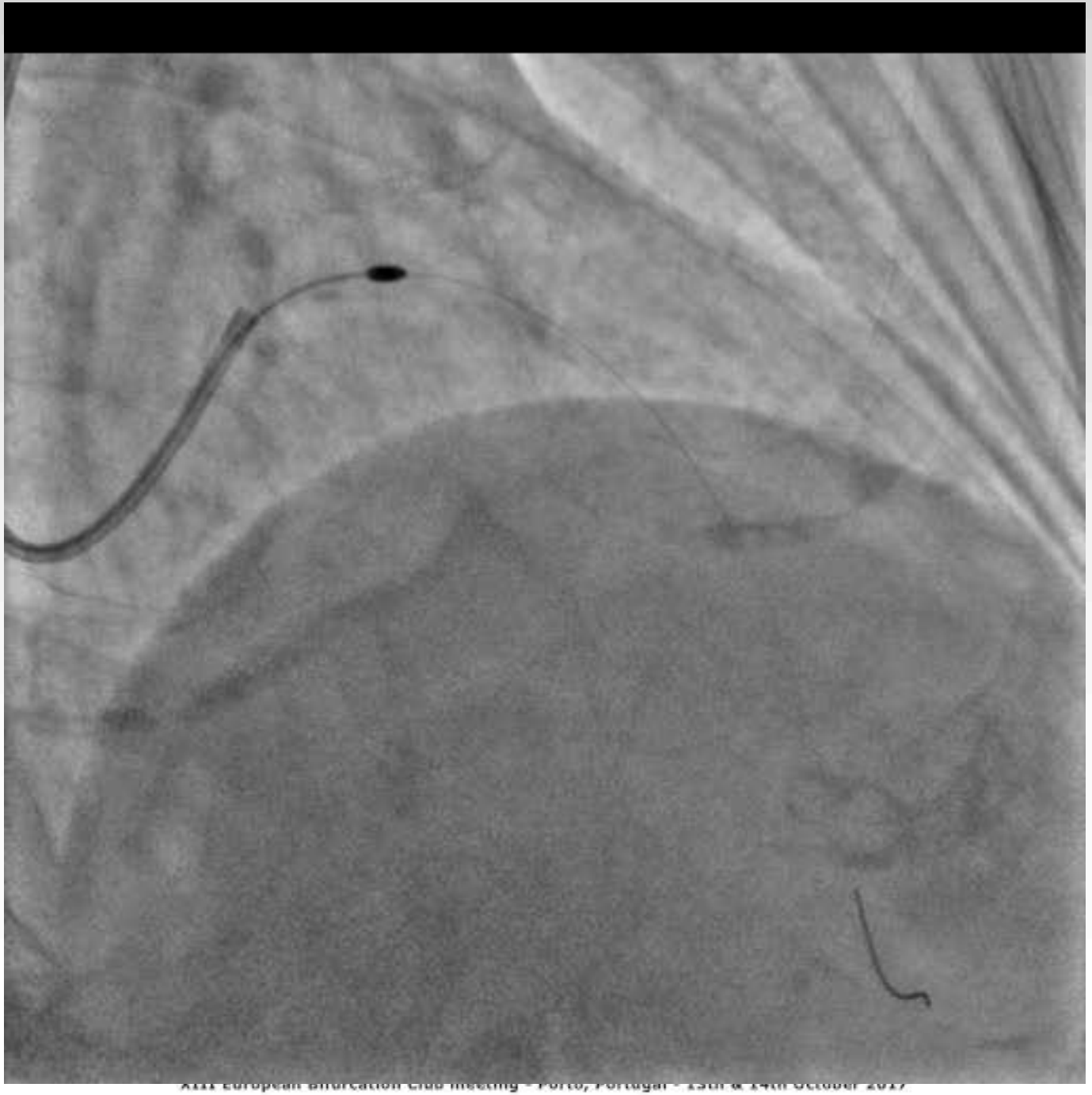

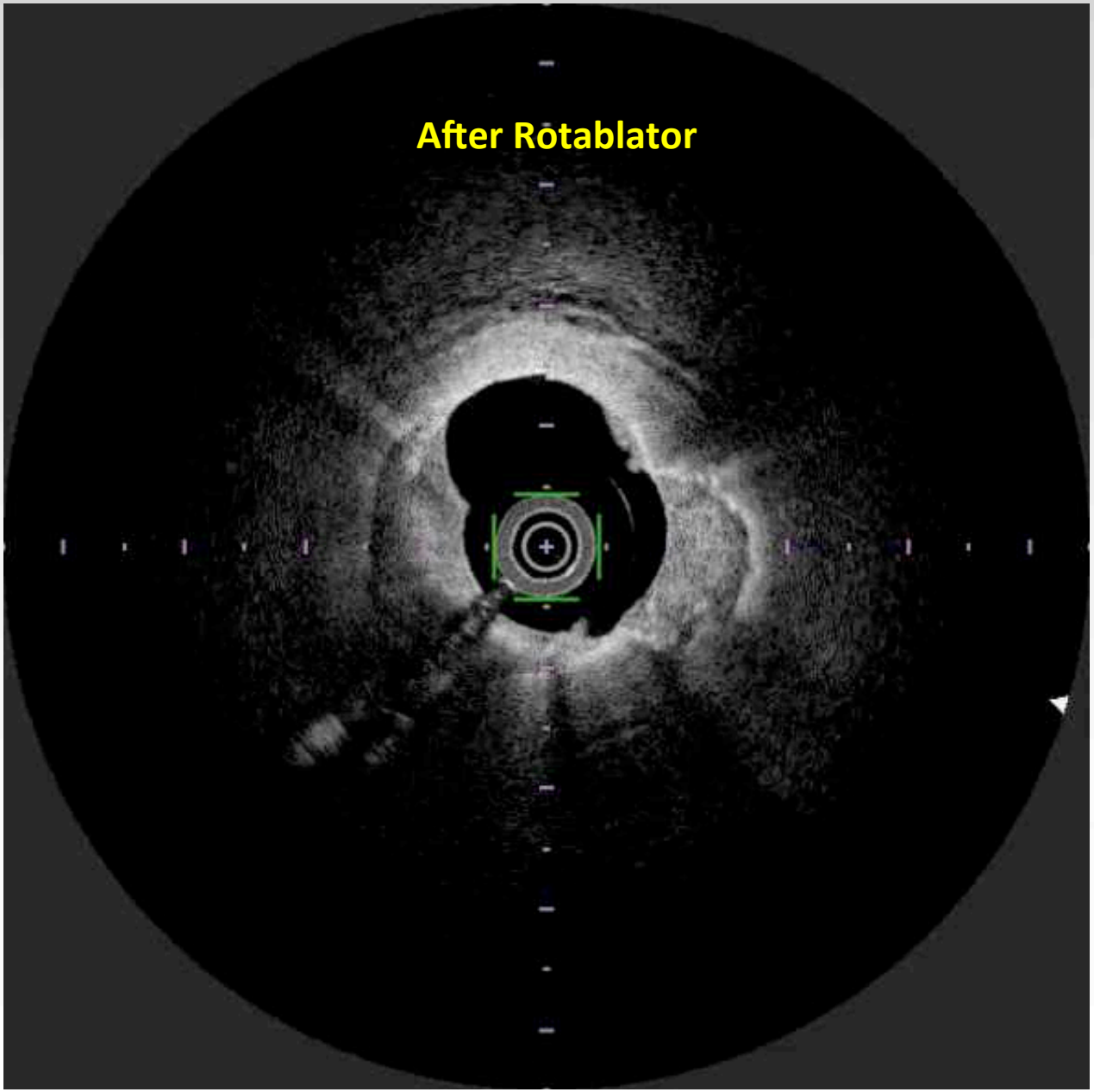
After Rotablator


TERUMO
Light Source
Scan Motor
MDU
Convert Value B
LAD#7Pre_1
ID: ******
2014-JUL-30
12:17:18
Pullback Speed: 40mm/sec
Pullback Length: 131.3mm
0140 /0523
Pre
STC
Gain: 10
Contrast: 7
Gamma: 1
Depth: 4.5
Flush Media: Contrast (75%)
FastView
Distal
50
Proximal
33.8mm[131.3mm]
LAD#7Post_3
ID: ******
2014-JUL-30
12:52:48
Pullback Speed: 40mm/sec
Pullback Length: 90.5mm
0151 /0363
Post Rota in LAD
STC
Gain: 10
Contrast: 7
Gamma: 1
Depth: 4.5
Flush Media: Contrast (75%)
FastView
Distal
50
Proximal
36.6mm[90.5mm]
Playback Control
Speed
mm/s
Frames
1mm
Step
LAD#7Pre_1
LAD#9Pre_2
LAD#7Post_3
LAD#9
Other#9Post_5
LAD#7Post_6
SYNC
ASYNC
Default View
Playback Control
Speed 4
mm/s
Frames
1mm
Step
2014 - AUG - 27 09:50
HDD
Logoff

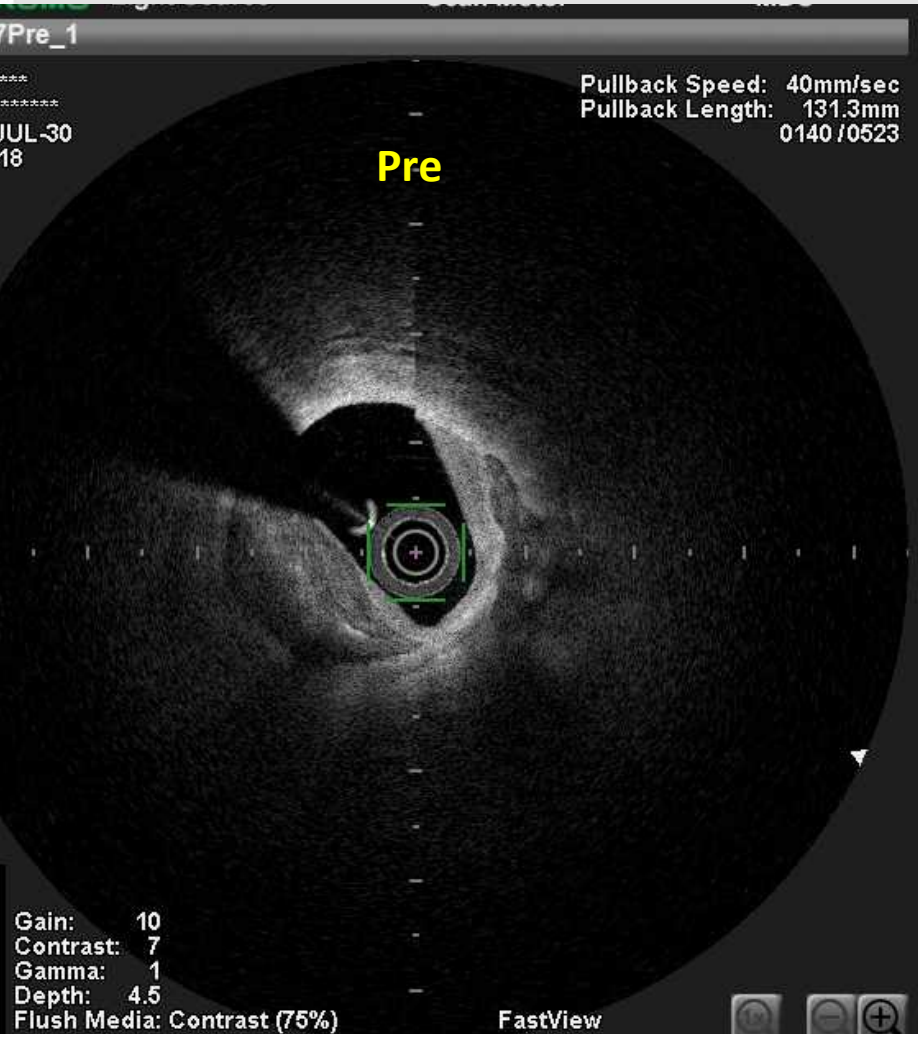
7Pre_1
Pullback Speed: 40mm/sec
Pullback Length: 131.3mm
0140 /0523
Pre
Gain: 10
Contrast: 7
Gamma: 1
Depth: 4.5
Flush Media: Contrast (75%)
FastView

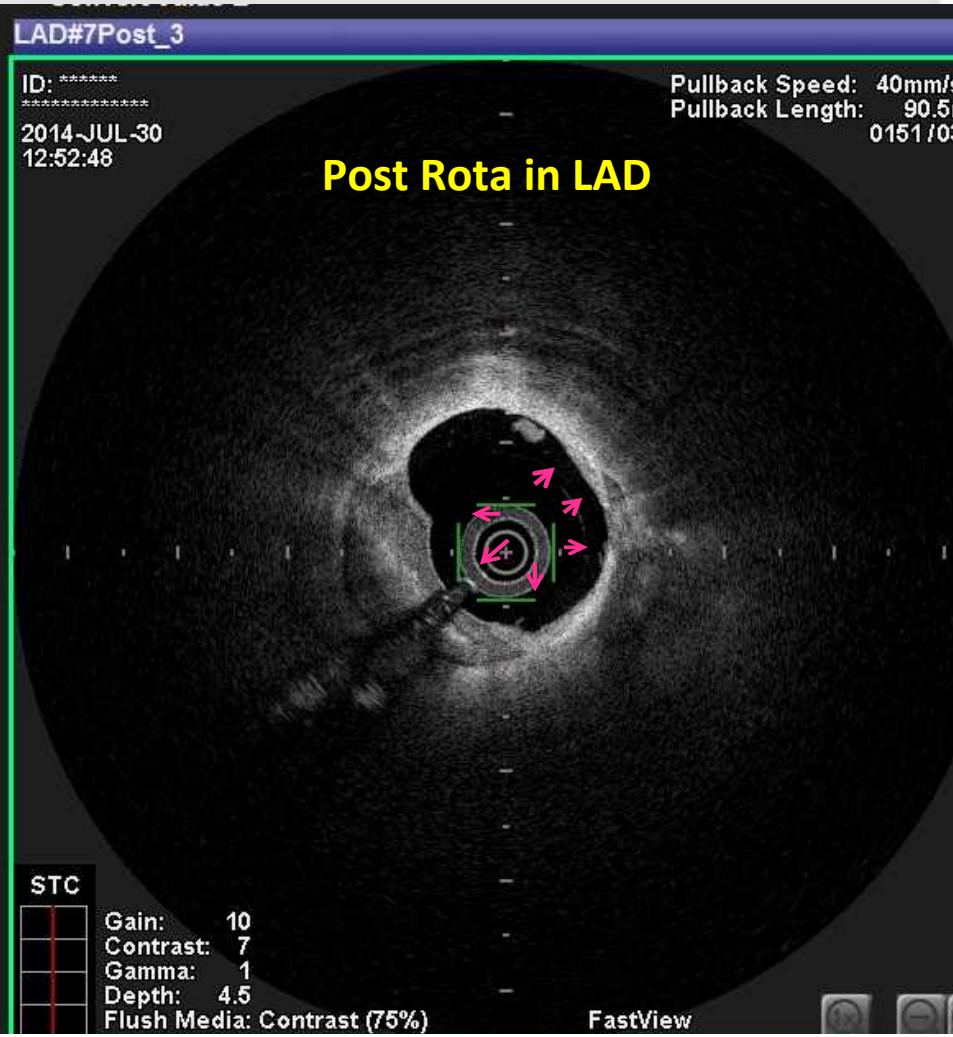
LAD#7Post_3
ID: ******
2014-JUL-30
12:52:48
Pullback Speed: 40mm/
Pullback Length: 90.5
0151 /0
Post Rota in LAD
STC
Gain: 10
Contrast: 7
Gamma: 1
Depth: 4.5
Flush Media: Contrast (75%)
FastView


TERUMO
Light Source
Scan Motor
MDU
Convert Value B
LAD#7Pre_1
ID: ******
2014-JUL-30
12:17:18
Pullback Speed: 40mm/sec
Pullback Length: 131.3mm
0140 / 0523
Pre
STC
Gain: 10
Contrast: 7
Gamma: 1
Depth: 4.5
Flush Media: Contrast (75%)
FastView
Distal
50
Proximal
33.8mm[131.3mm]
LAD#7Post_3
ID: ******
2014-JUL-30
12:52:48
Pullback Speed: 40mm/sec
Pullback Length: 90.5mm
0151 / 0363
Post Rota in LAD
STC
Gain: 10
Contrast: 7
Gamma: 1
Depth: 4.5
Flush Media: Contrast (75%)
FastView
Distal
50
Proximal
36.6mm[90.5mm]
Playback Control
Speed
mm/s
Frames
1mm
Step
LAD#7Pre_1
LAD#9Pre_2
LAD#7Post_3
LAD#9
Other#9Post_5
LAD#7Post_6
SYNC
ASYNC
Default View
Playback Control
Speed 4
mm/s
Frames
1mm
Step
2014 - AUG - 27 09:50
HDD
Logoff

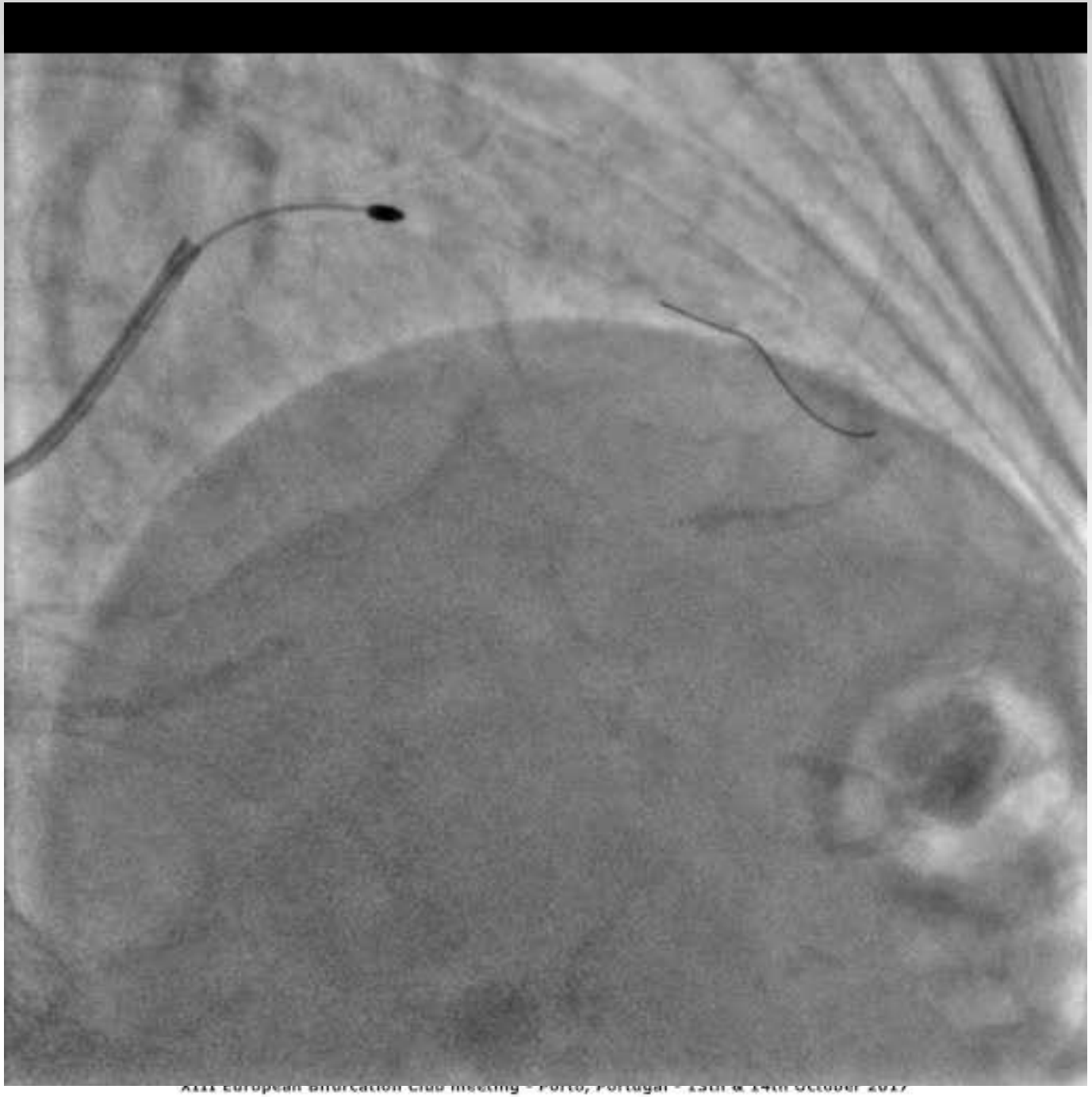

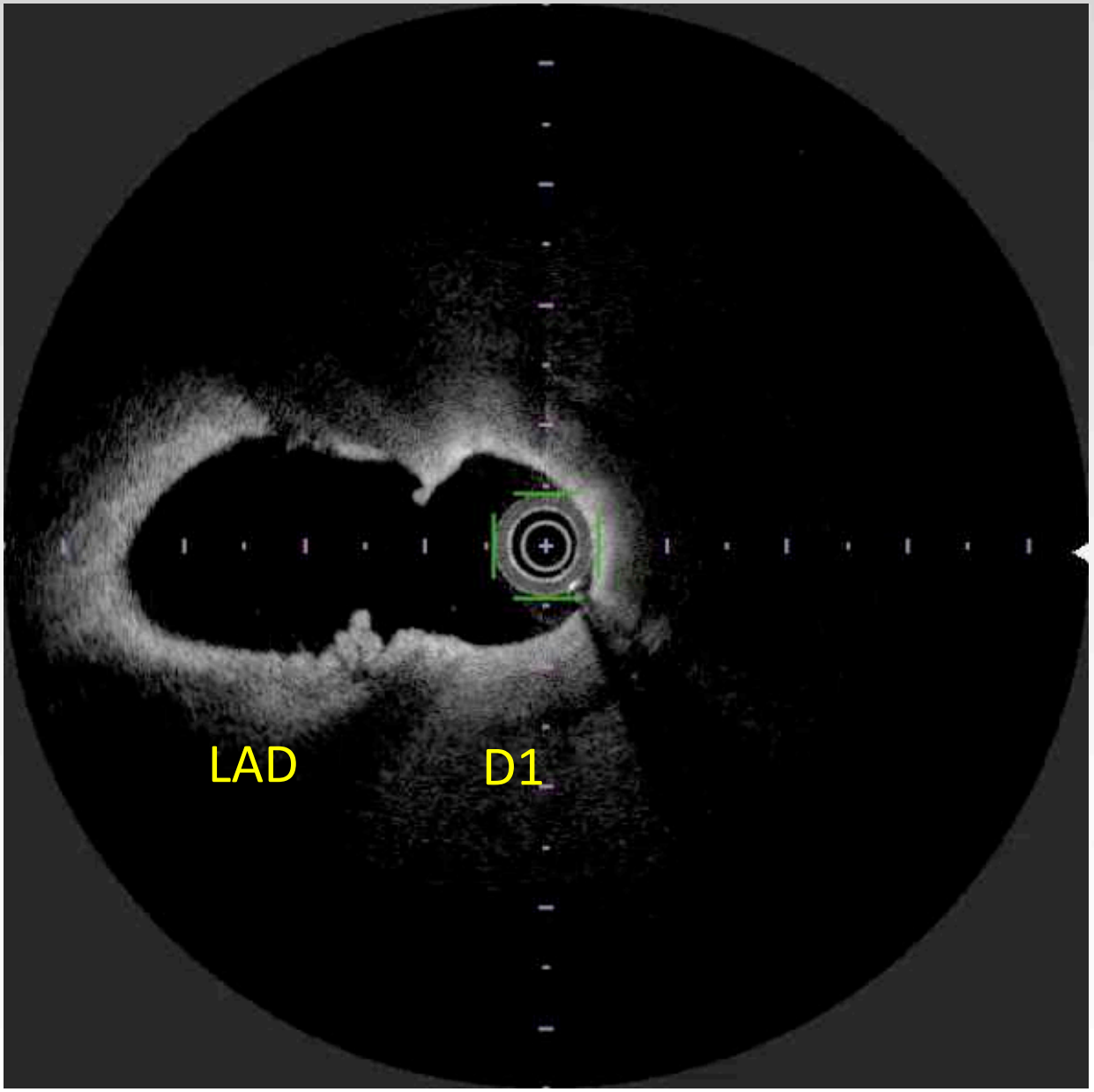
LAD
D1

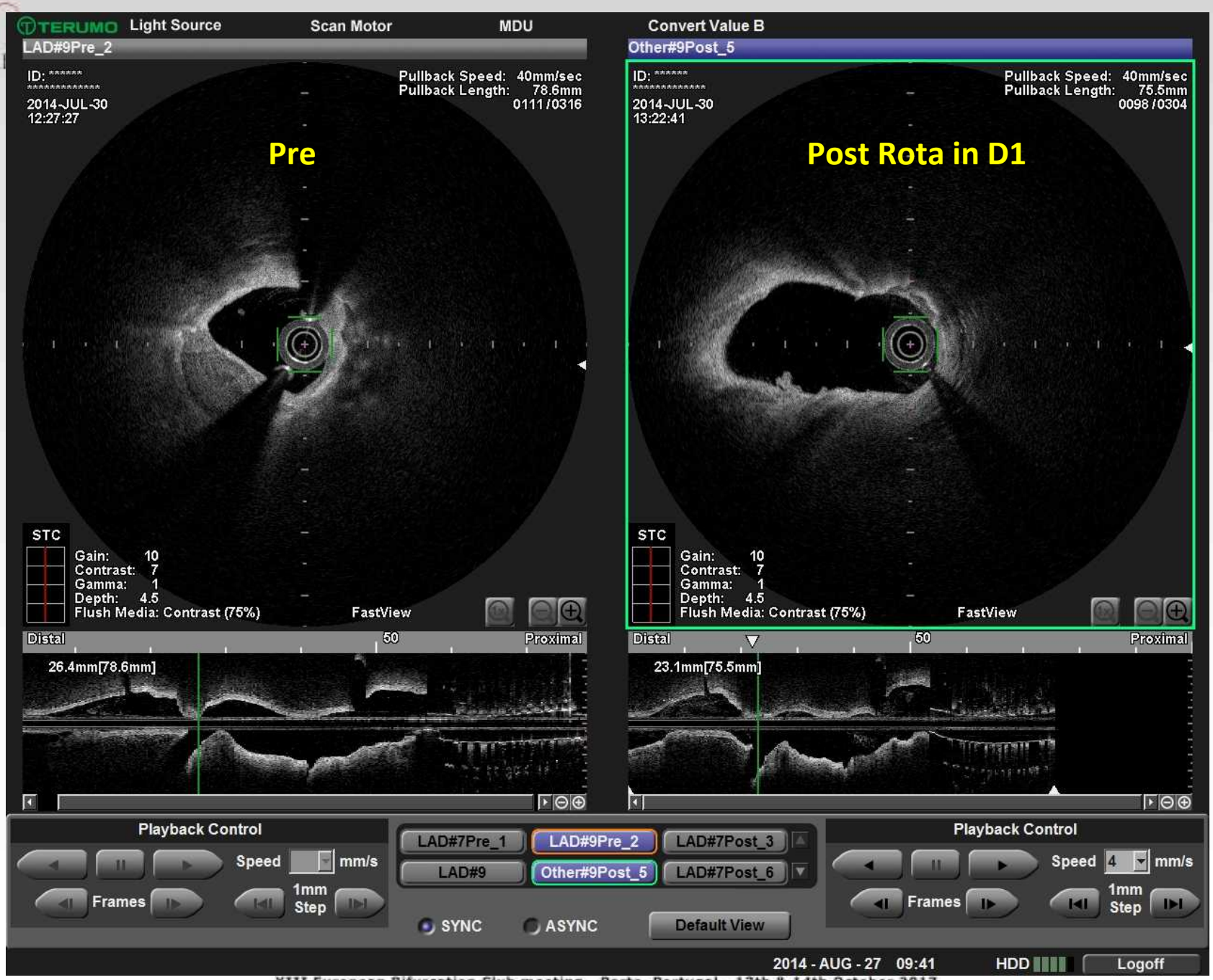
TERUMO
Light Source
Scan Motor
MDU
Convert Value B
LAD#9Pre_2
Other#9Post_5
ID: ******
2014-JUL-30
12:27:27
Pullback Speed: 40mm/sec
Pullback Length: 78.6mm
0111 /0316
Pre
ID: ******
2014-JUL-30
13:22:41
Pullback Speed: 40mm/sec
Pullback Length: 75.5mm
0098 /0304
Post Rota in D1
STC
Gain: 10
Contrast: 7
Gamma: 1
Depth: 4.5
Flush Media: Contrast (75%)
FastView
Distal
50
Proximal
26.4mm[78.6mm]
23.1mm[75.5mm]
Playback Control
Speed
mm/s
Frames
1mm Step
LAD#7Pre_1
LAD#9Pre_2
LAD#7Post_3
LAD#9
Other#9Post_5
LAD#7Post_6
SYNC
ASYNC
Default View
2014 - AUG - 27 09:41
HDD
Logoff

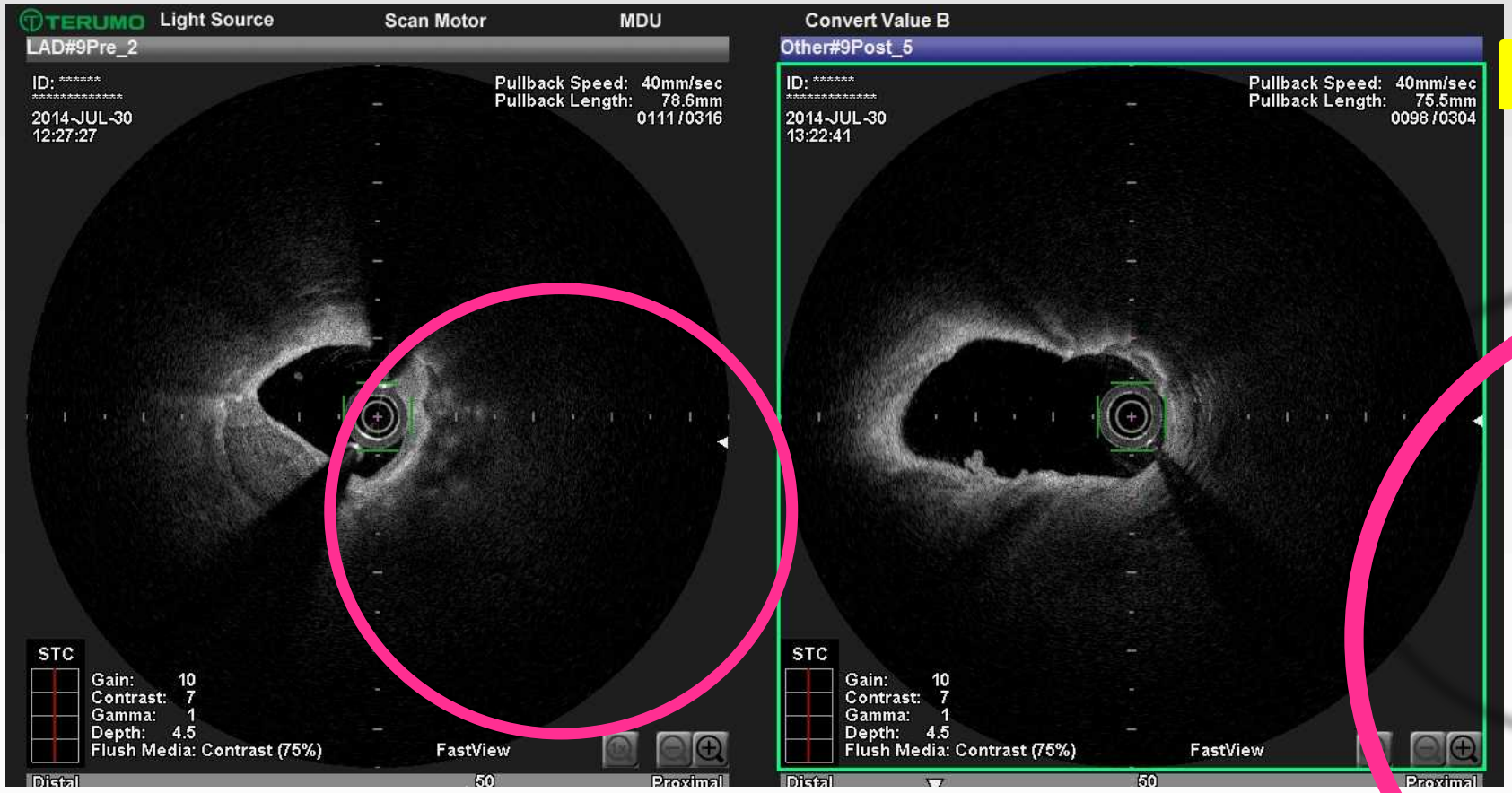
TERUMO
Light Source
Scan Motor
MDU
Convert Value B
LAD#9Pre_2
ID: ******
2014-JUL-30
12:27:27
Pullback Speed: 40mm/sec
Pullback Length: 78.6mm
0111 /0316
STC
Gain: 10
Contrast: 7
Gamma: 1
Depth: 4.5
Flush Media: Contrast (75%)
FastView
Distal
50
Proximal
Other#9Post_5
ID: ******
2014-JUL-30
13:22:41
Pullback Speed: 40mm/sec
Pullback Length: 75.5mm
0098 /0304
STC
Gain: 10
Contrast: 7
Gamma: 1
Depth: 4.5
Flush Media: Contrast (75%)
FastView
Distal
50
Proximal

Po


TERUMO
Light Source
Scan Motor
MDU
Convert Value B
LAD#9Pre_2
Other#9Post_5
ID: ******
2014-JUL-30
12:27:27
Pullback Speed: 40mm/sec
Pullback Length: 78.6mm
0111 /0316
ID: ******
2014-JUL-30
13:22:41
Pullback Speed: 40mm/sec
Pullback Length: 75.5mm
0098 /0304
STC
Gain: 10
Contrast: 7
Gamma: 1
Depth: 4.5
Flush Media: Contrast (75%)
FastView
Distal
50
Proximal
26.4mm[78.6mm]
23.1mm[75.5mm]
Playback Control
Speed
mm/s
Frames
1mm Step
LAD#7Pre_1
LAD#9Pre_2
LAD#7Post_3
LAD#9
Other#9Post_5
LAD#7Post_6
SYNC
ASYNC
Default View
Playback Control
4
mm/s
Frames
1mm Step
2014 - AUG - 27 09:41
HDD
Logoff

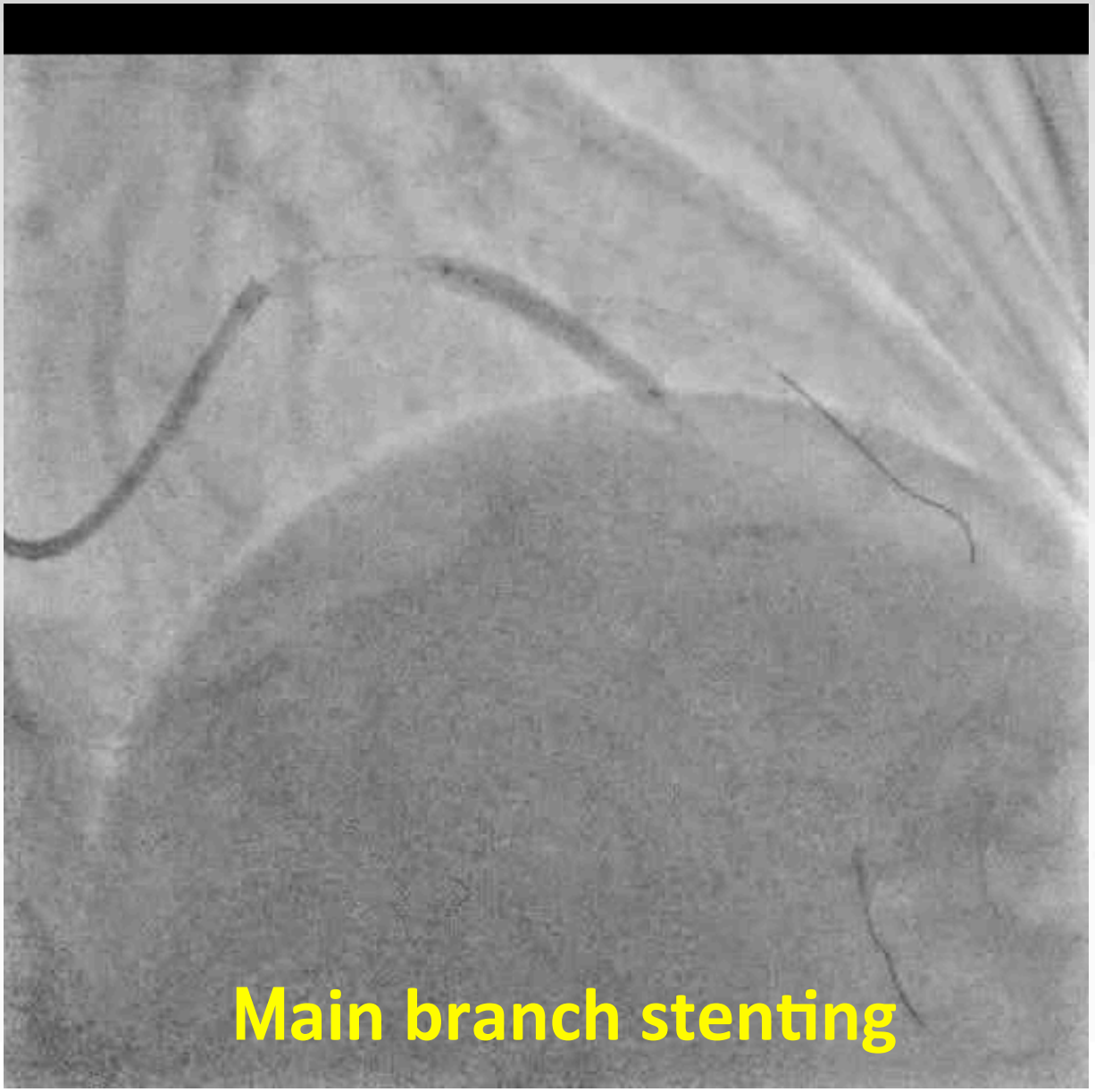
Main branch stenting

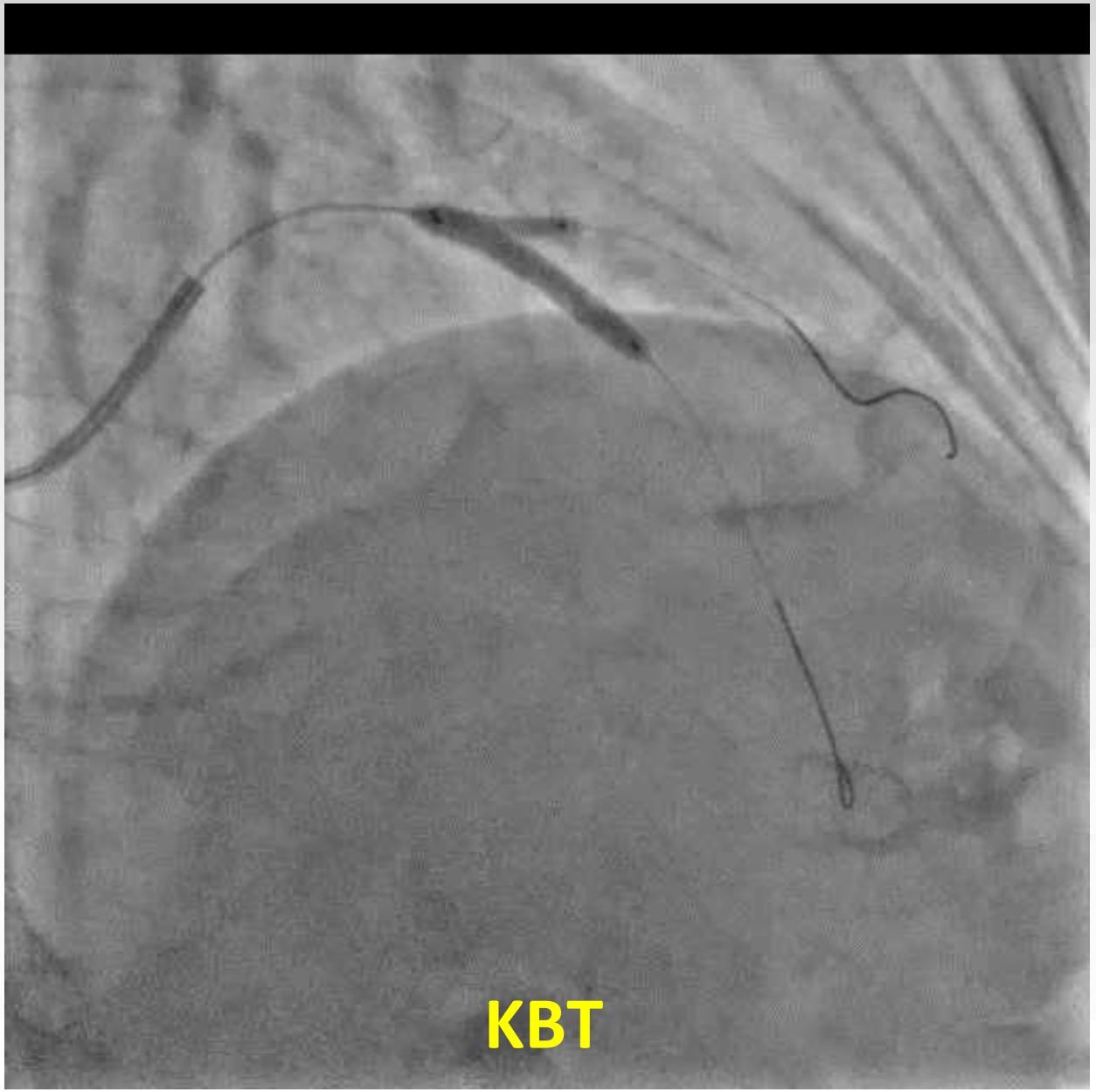
KBT

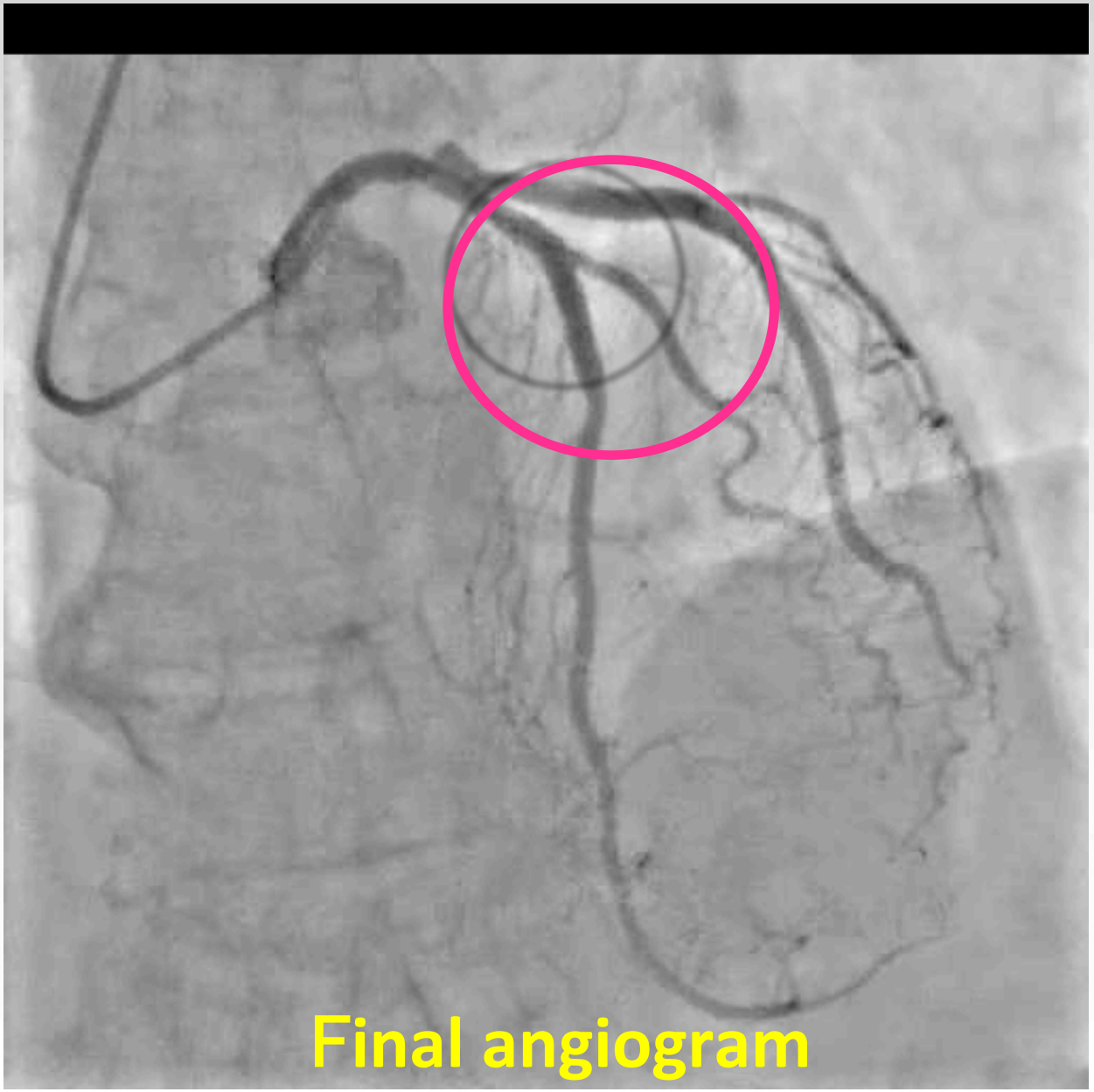
Final angiogram

SUMMARY

- Know plaque distribution
- Know carina shift
- Know wire bias
- Appropriate debulking (rotablation/DCA) may achieve good stent expansion but also reduce a chance of compromising of side branch and finally avoid complex stenting
- OCT/OFDI can identify the thickness of calcified plaque, so we can recognize the capacity of ablation of Rotablator in bifurcation site.
- OCT/OFDI is very useful imaging guidance for treatment bifurcation lesion, especially in lesion containing of hard and calcified plaque using Rotablator

case2

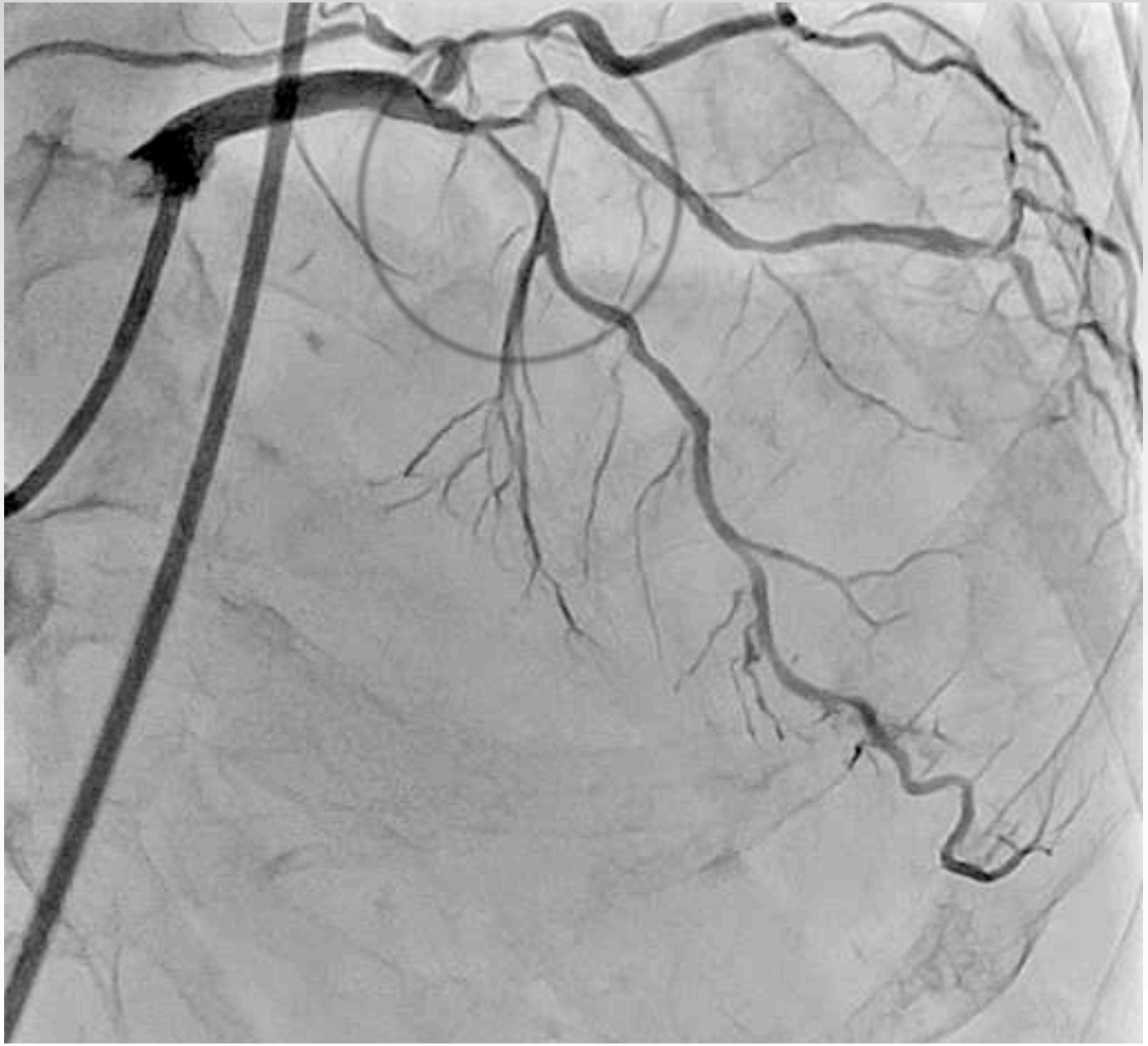

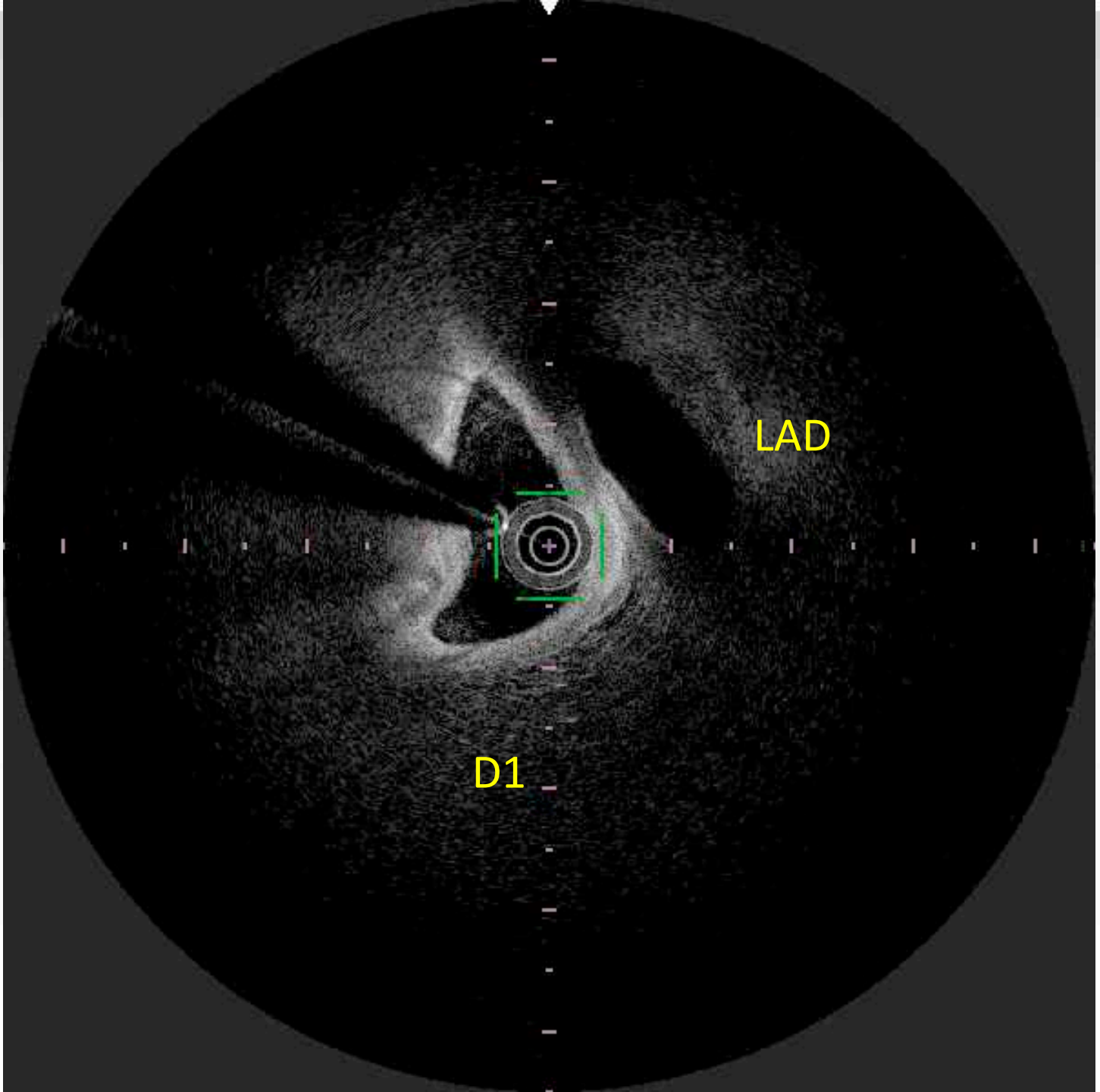
LAD
D1

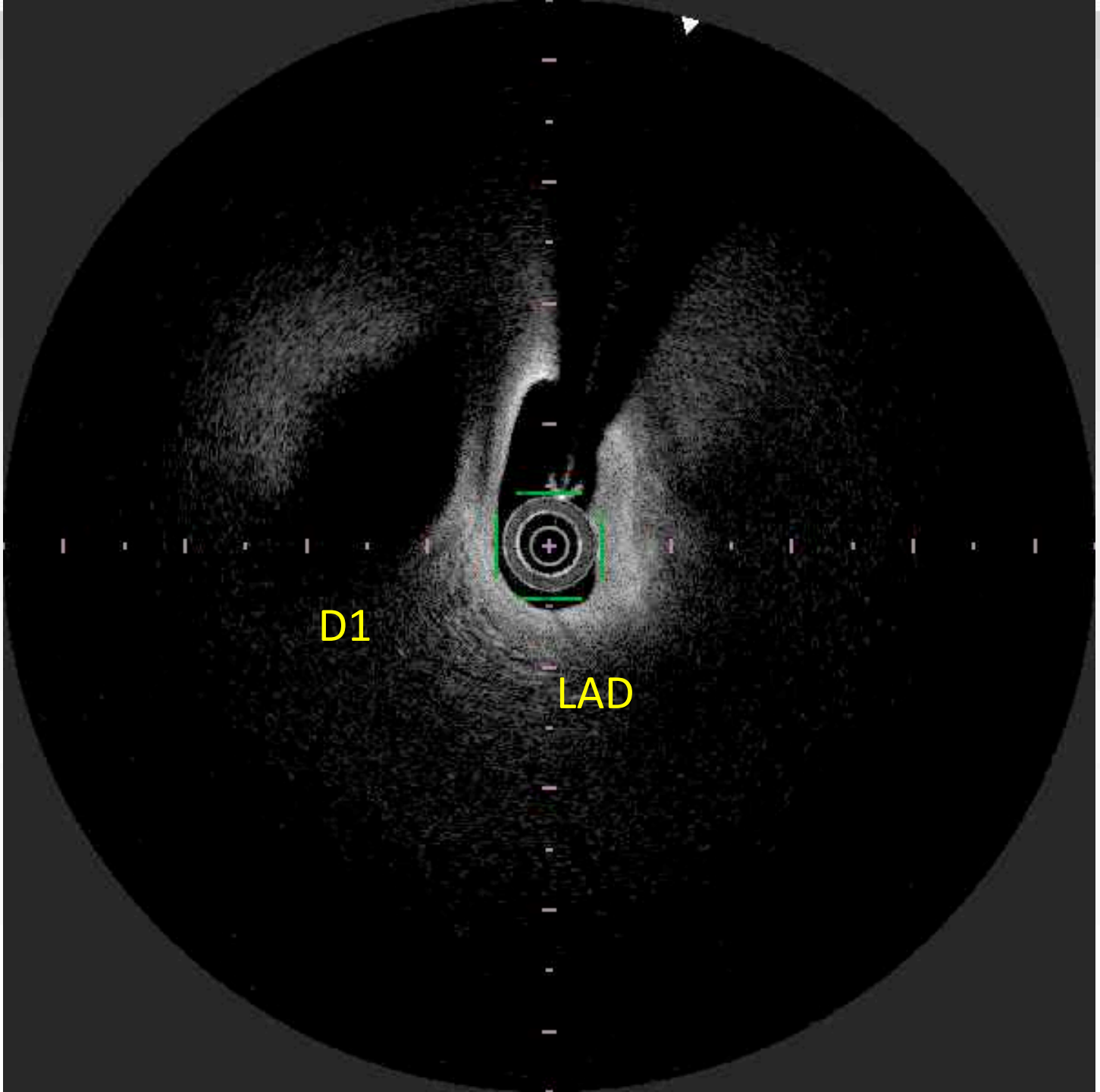
D1
LAD

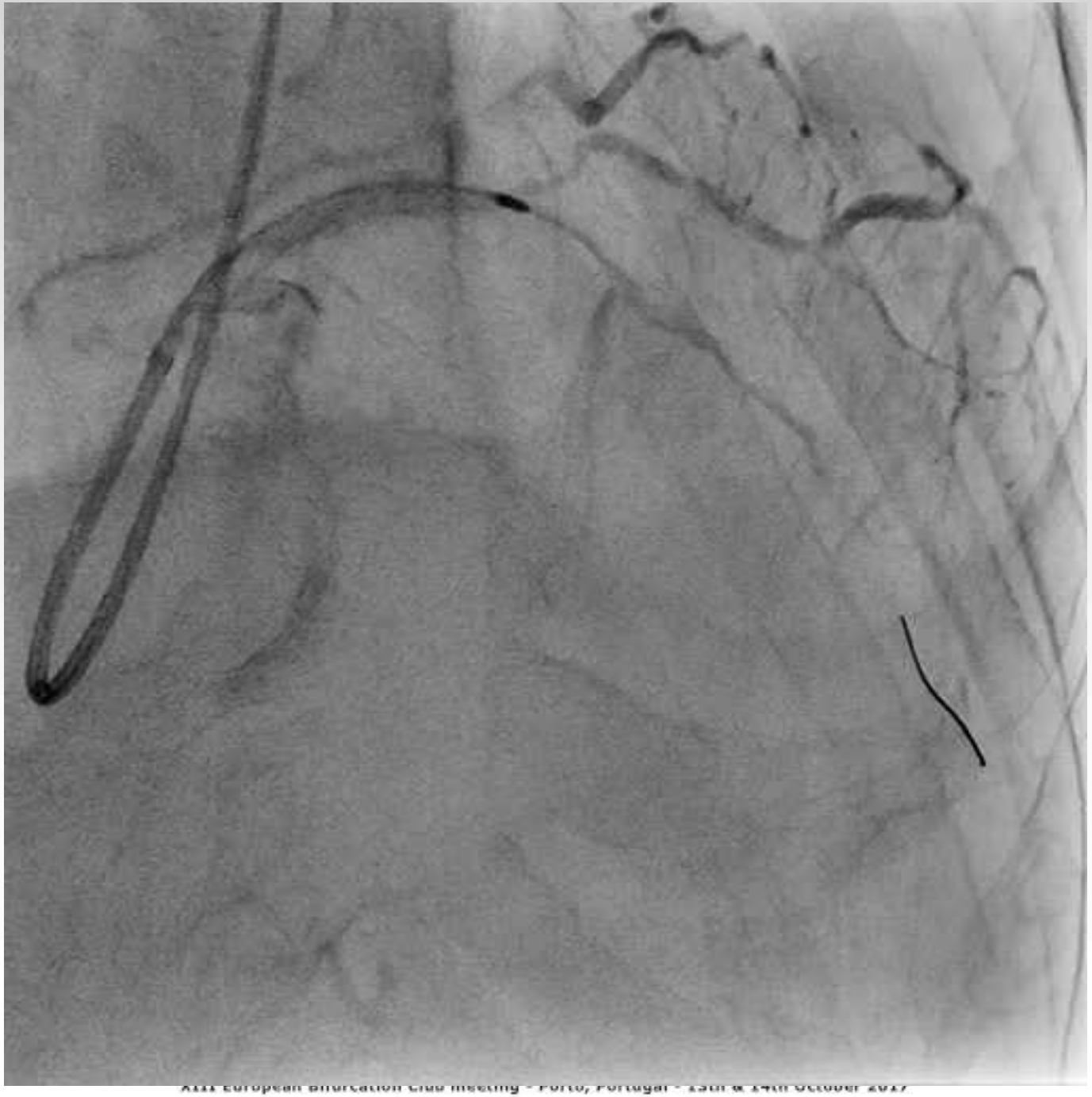

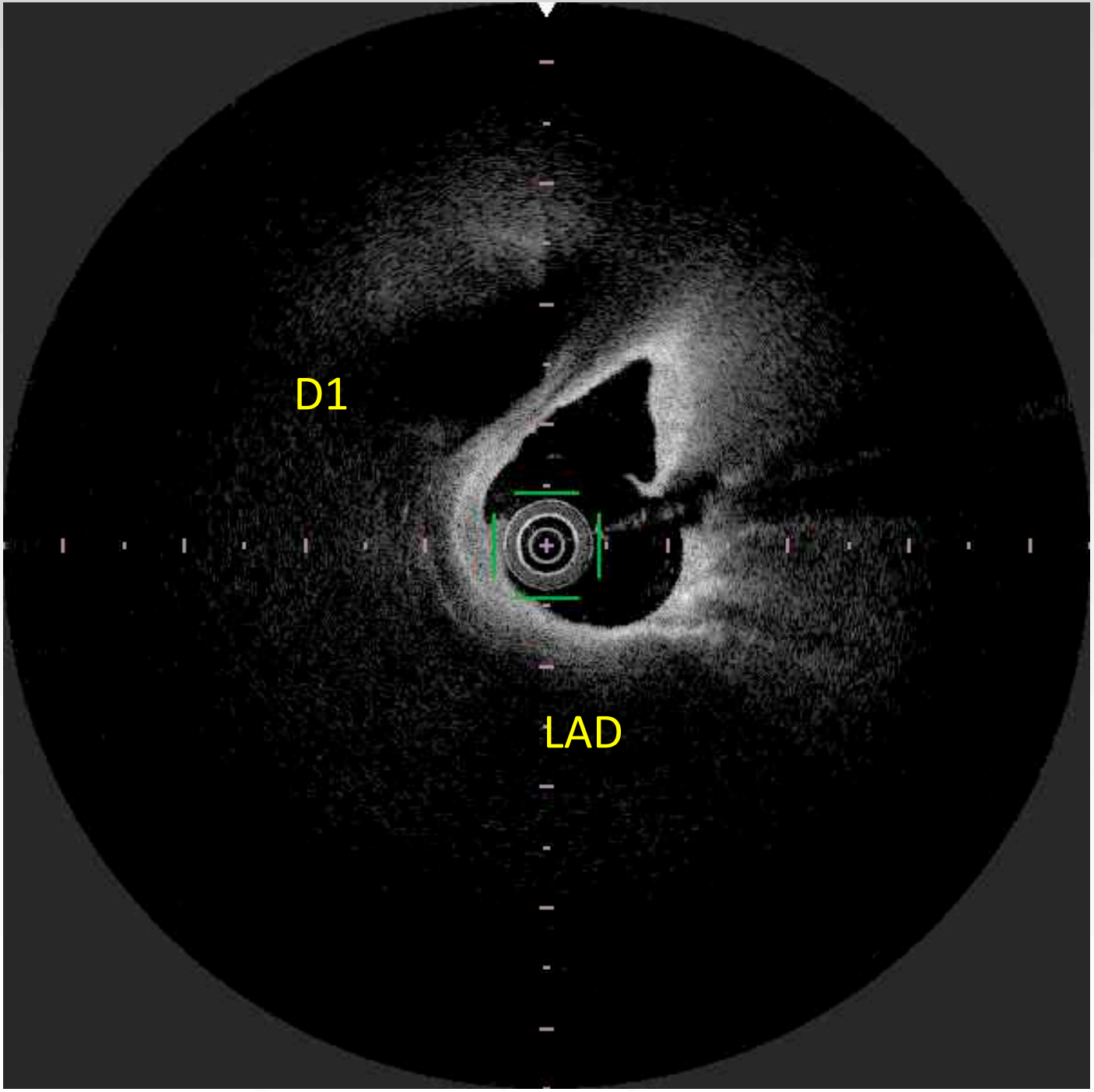
D1
LAD

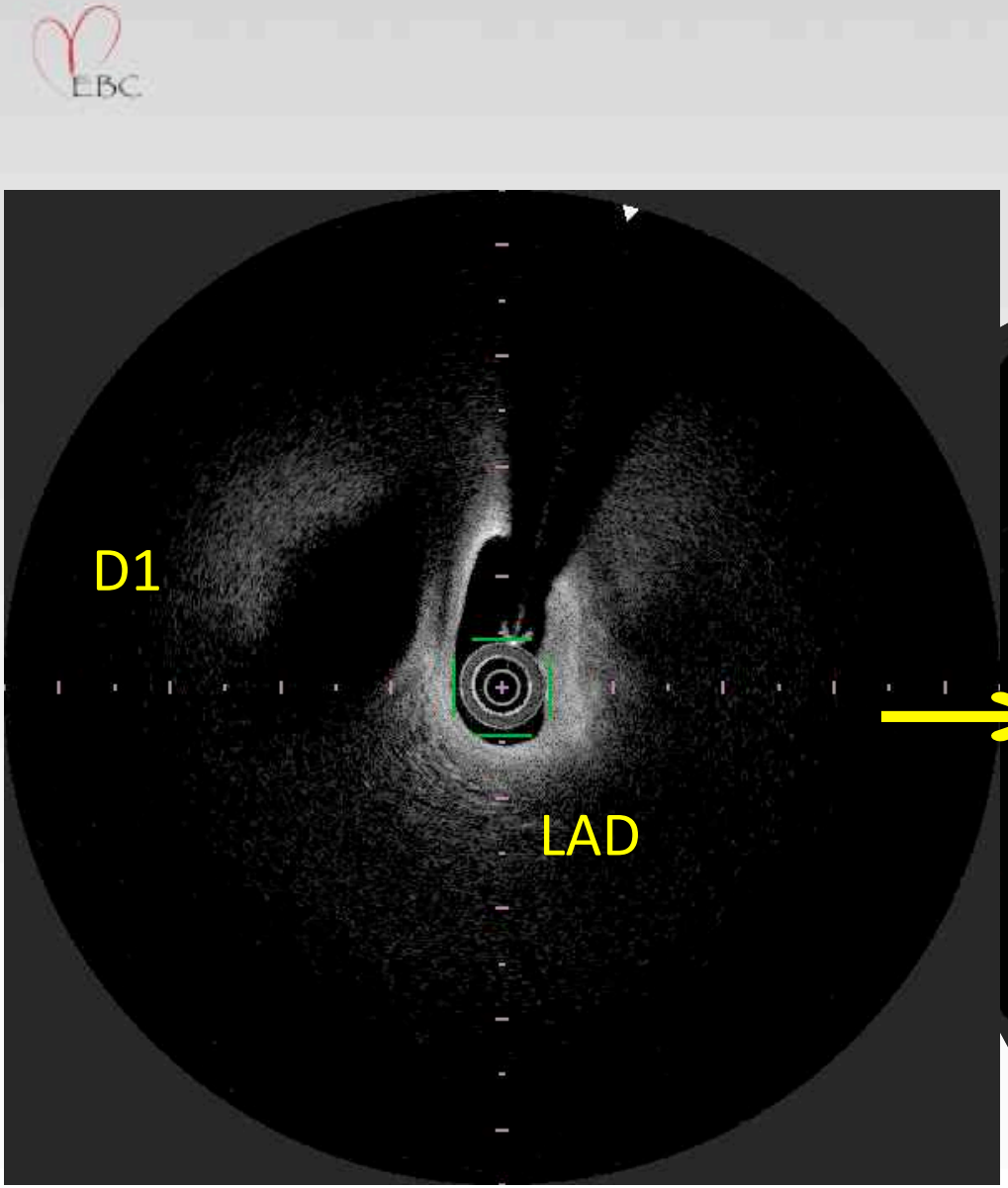
D1
LAD

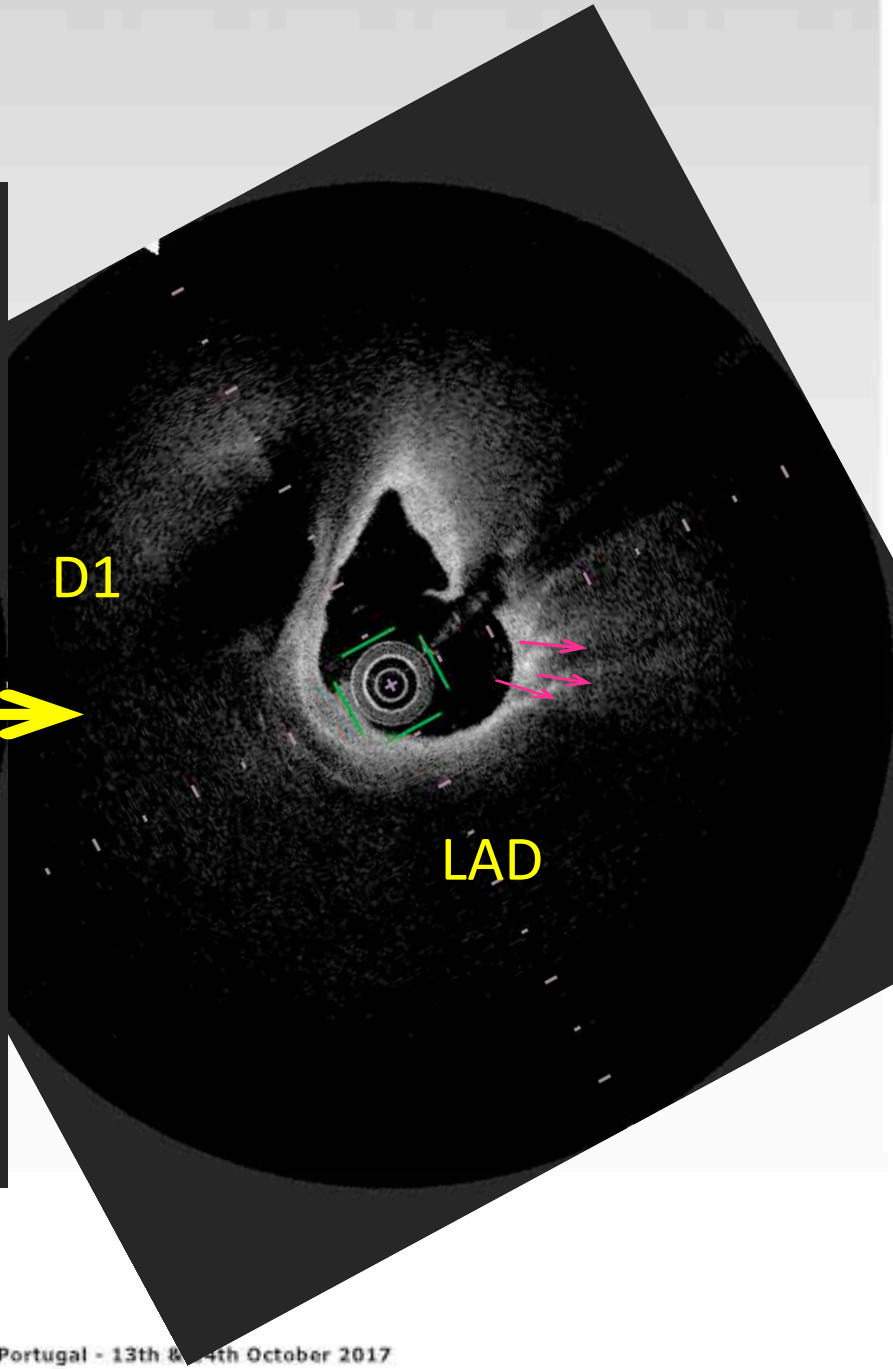
D1
LAD

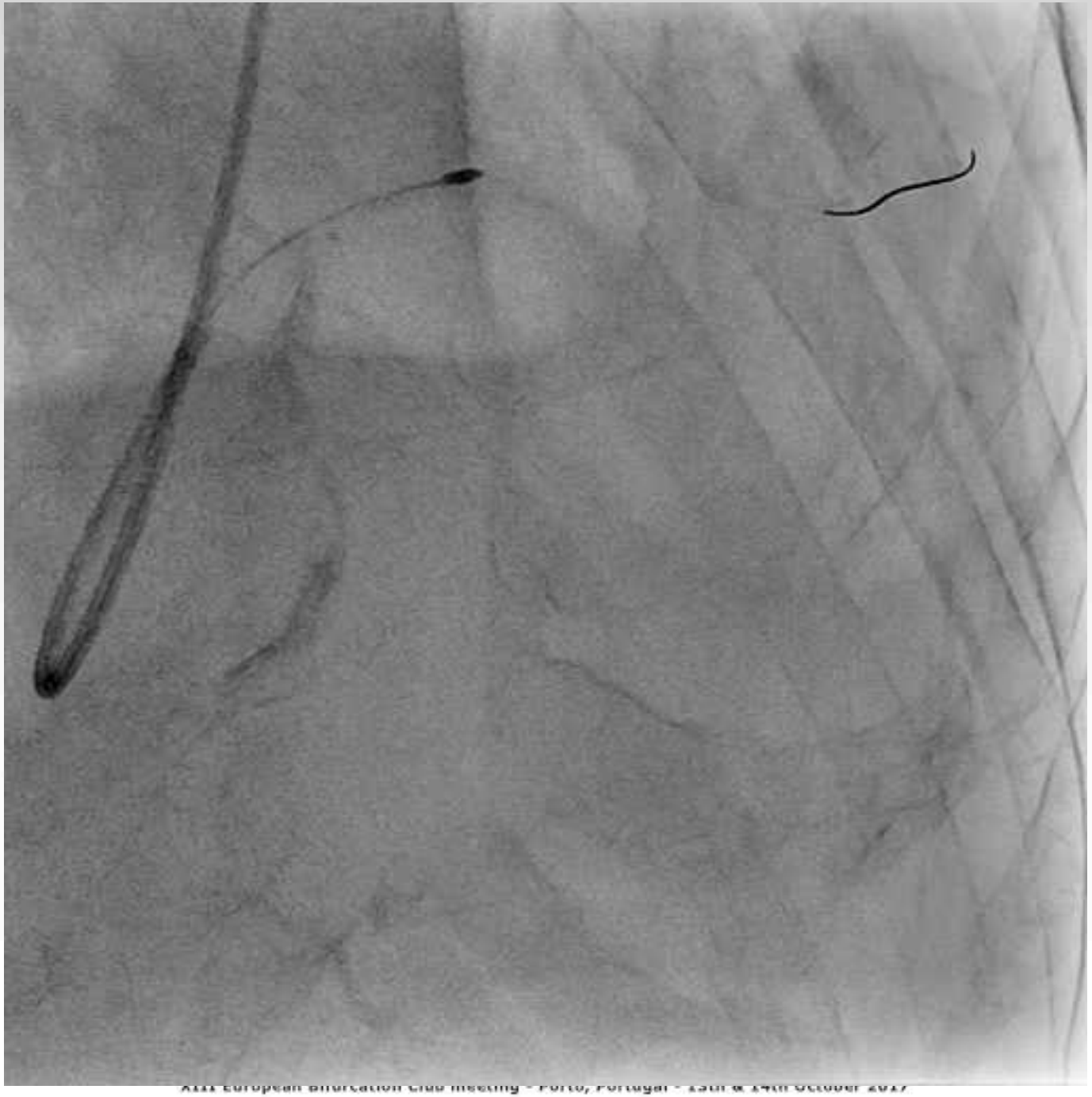

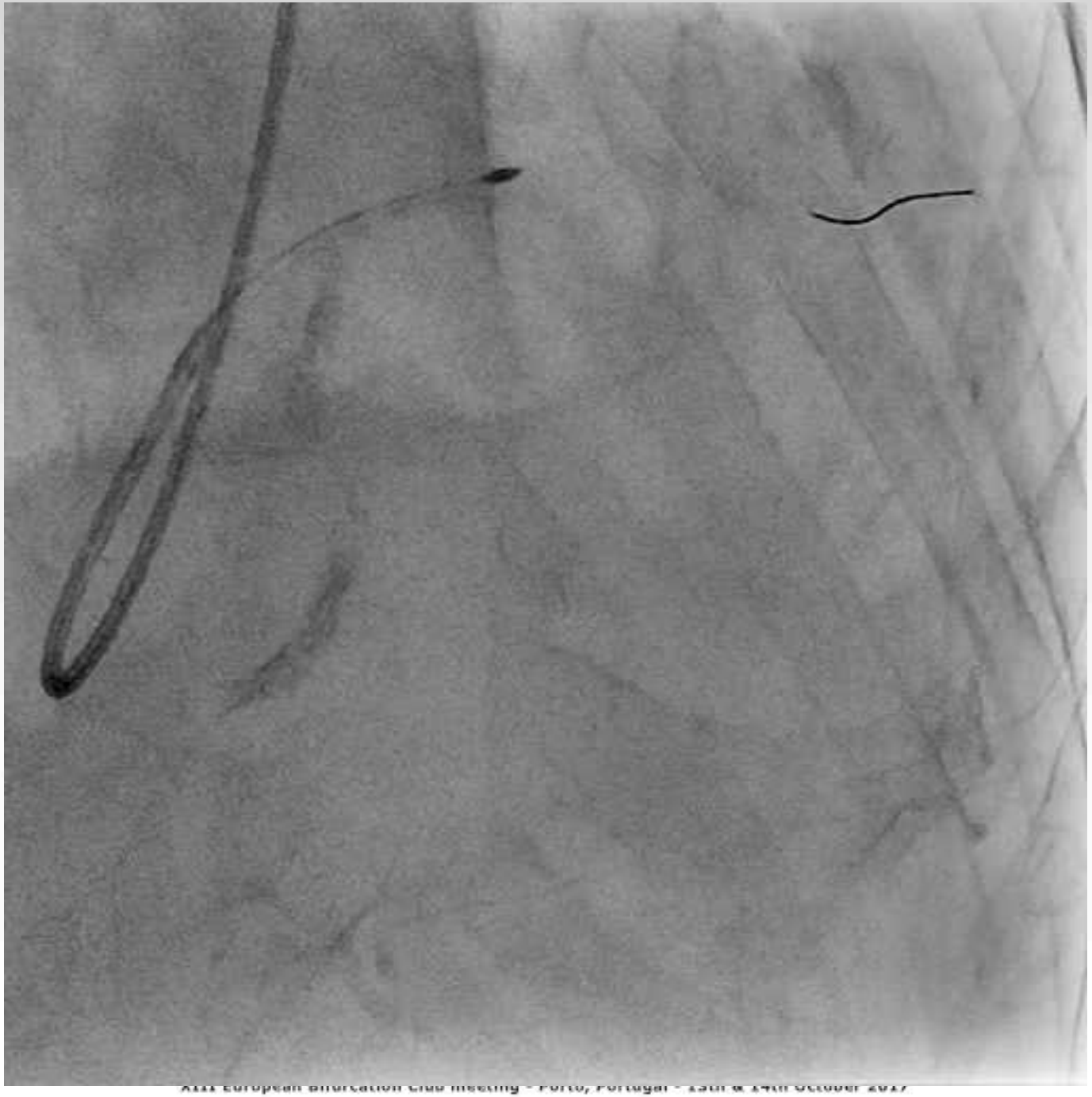

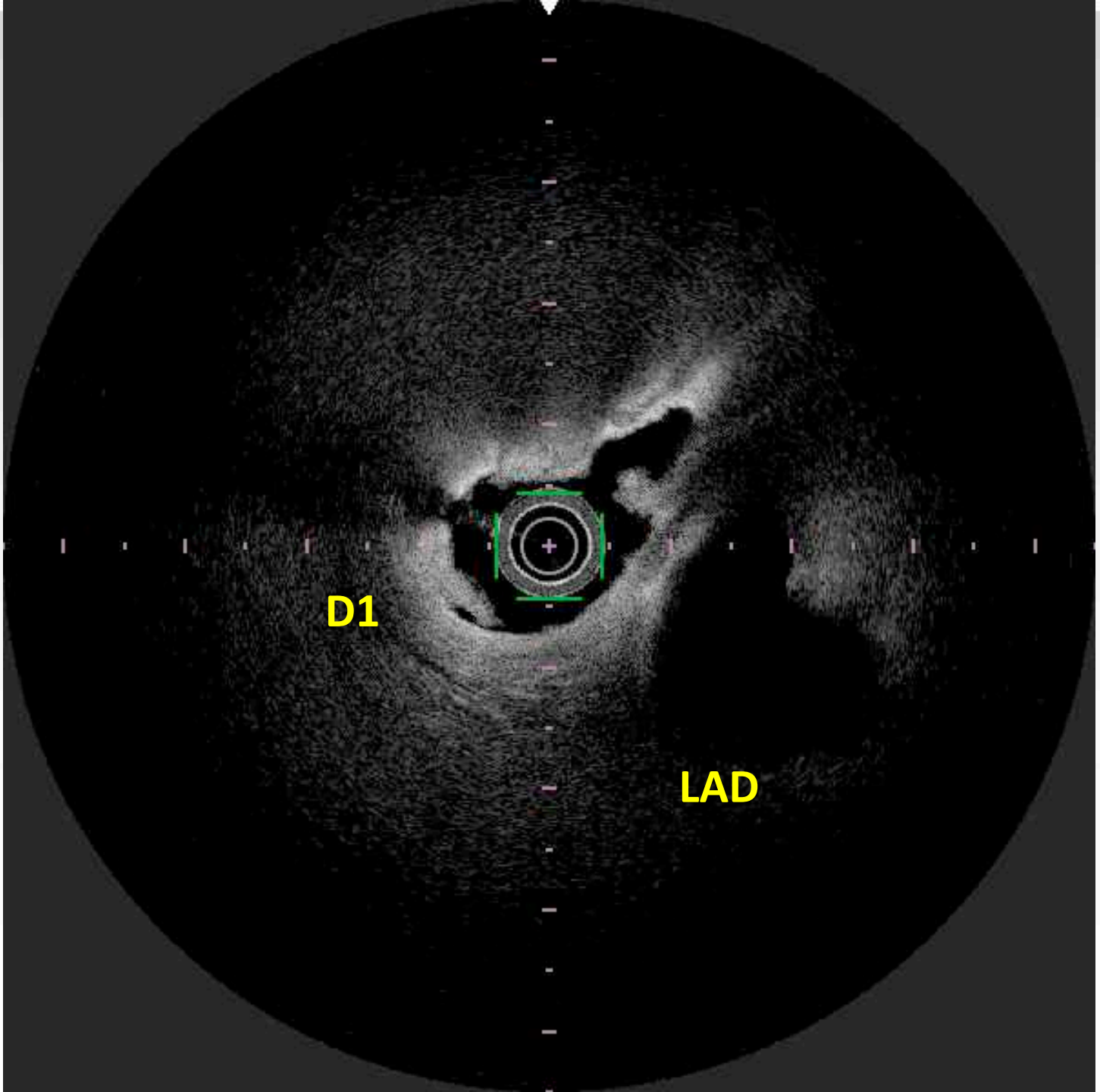
D1
LAD

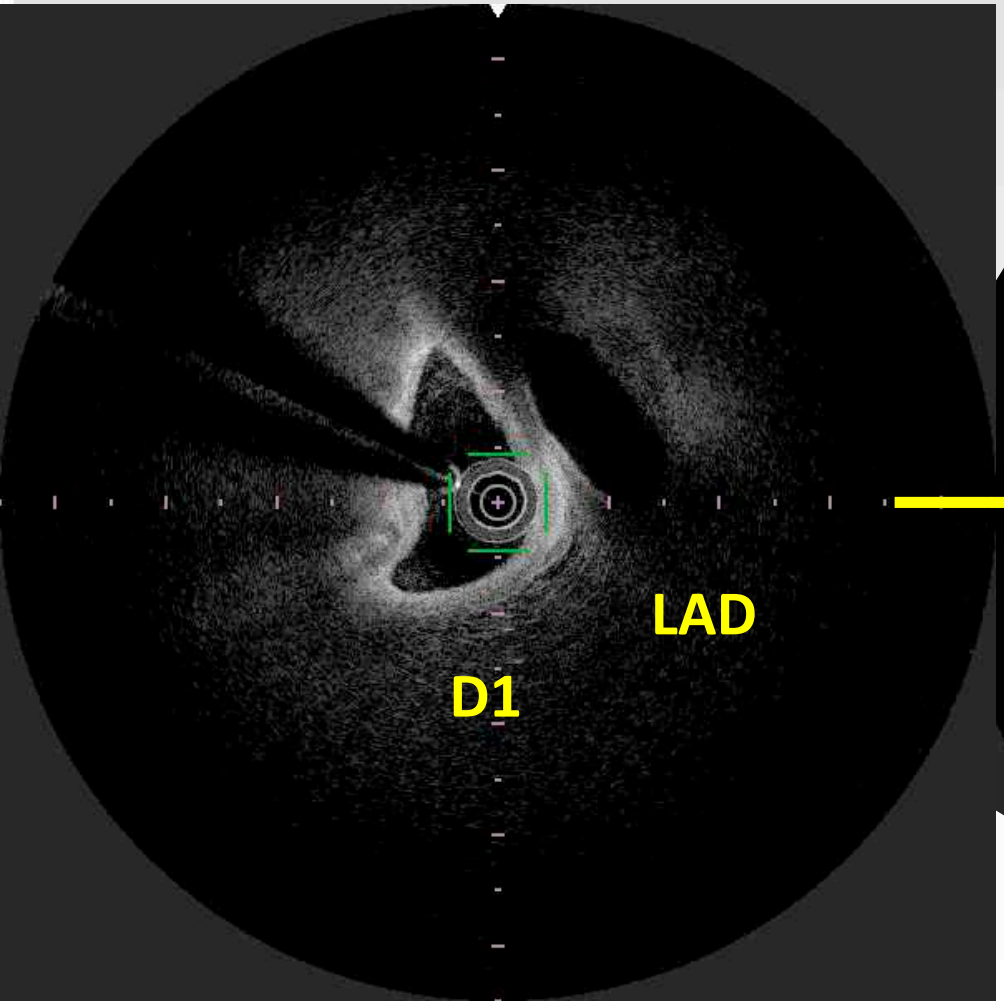
LAD
D1

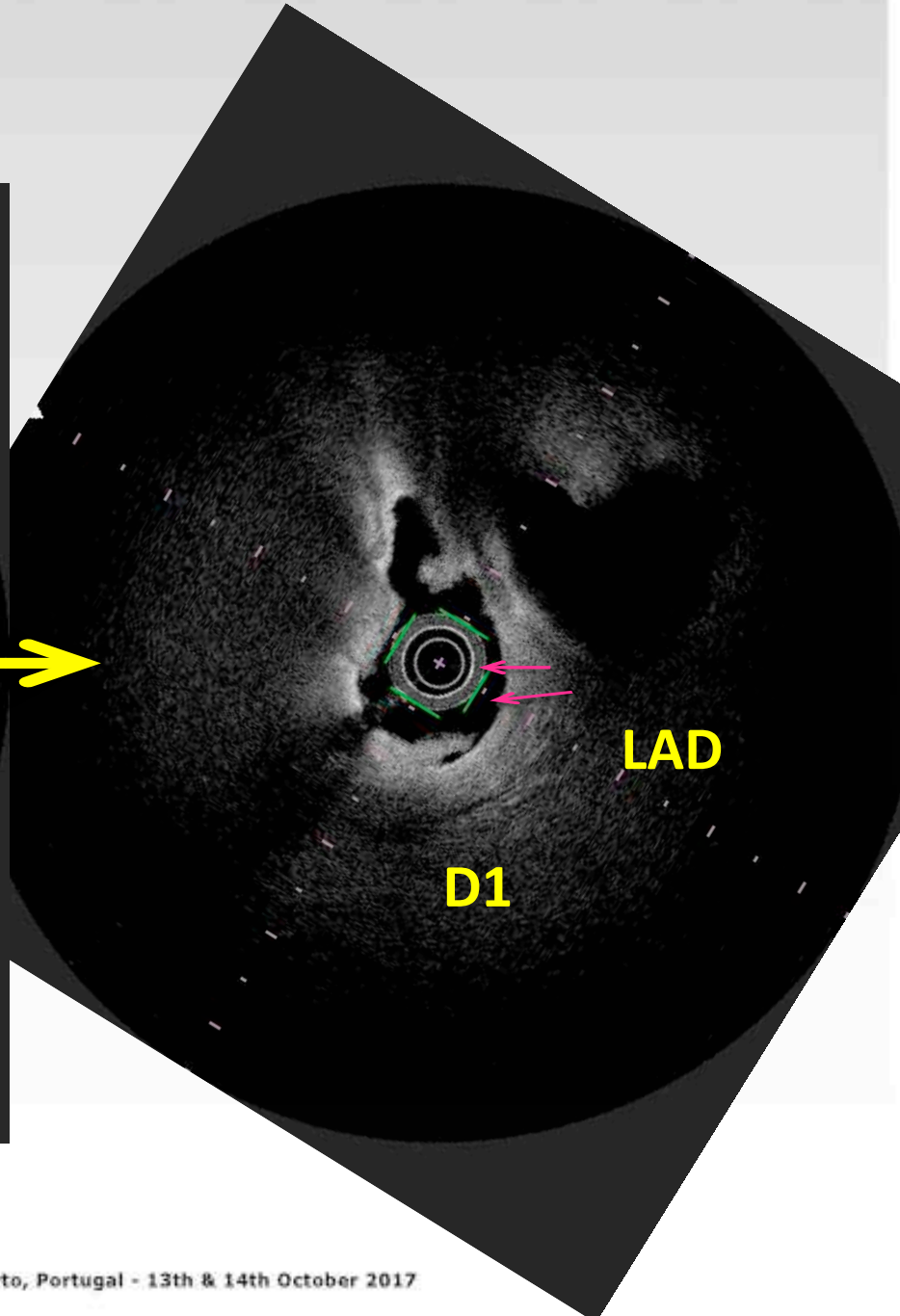
LAD
D1

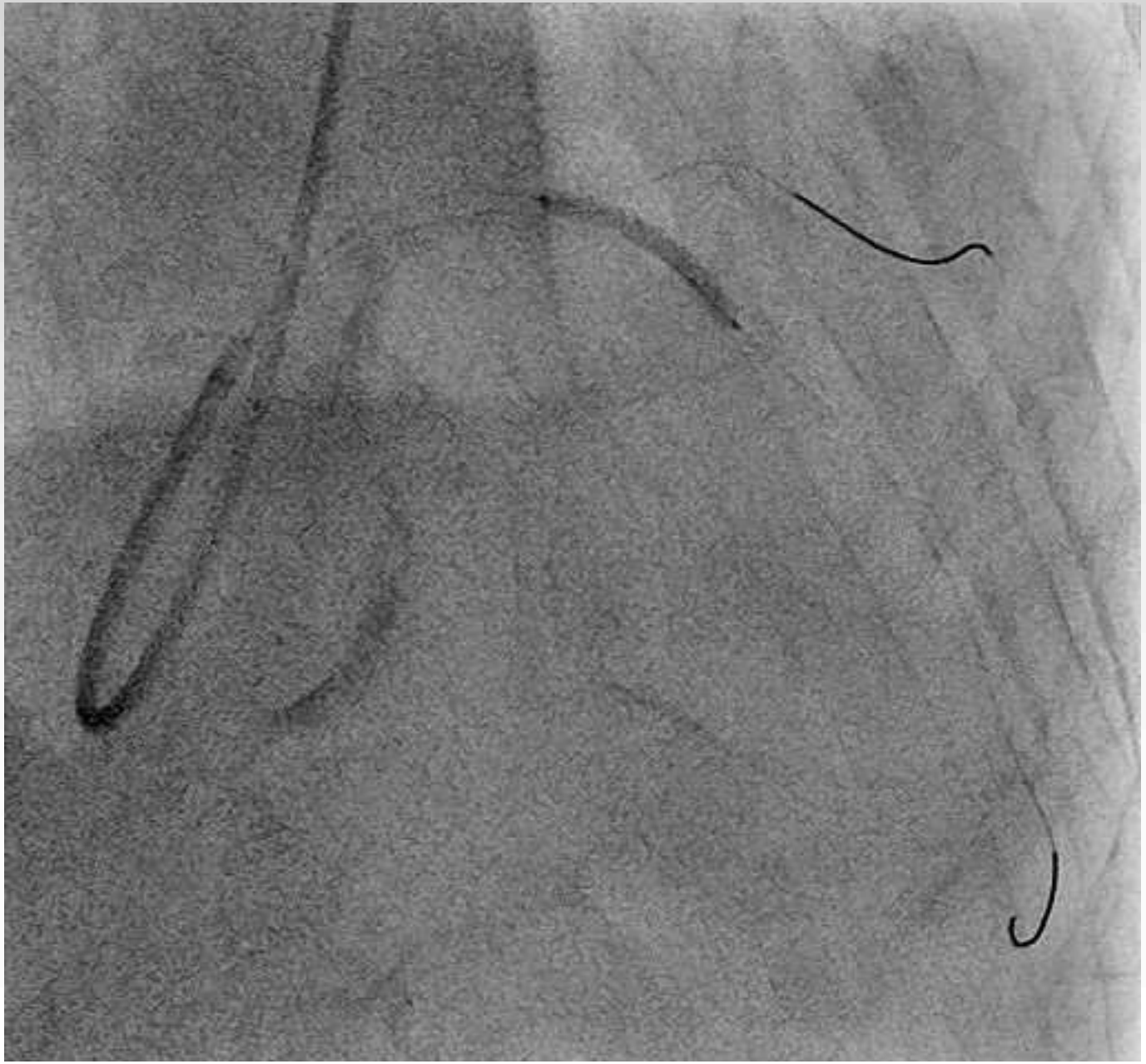

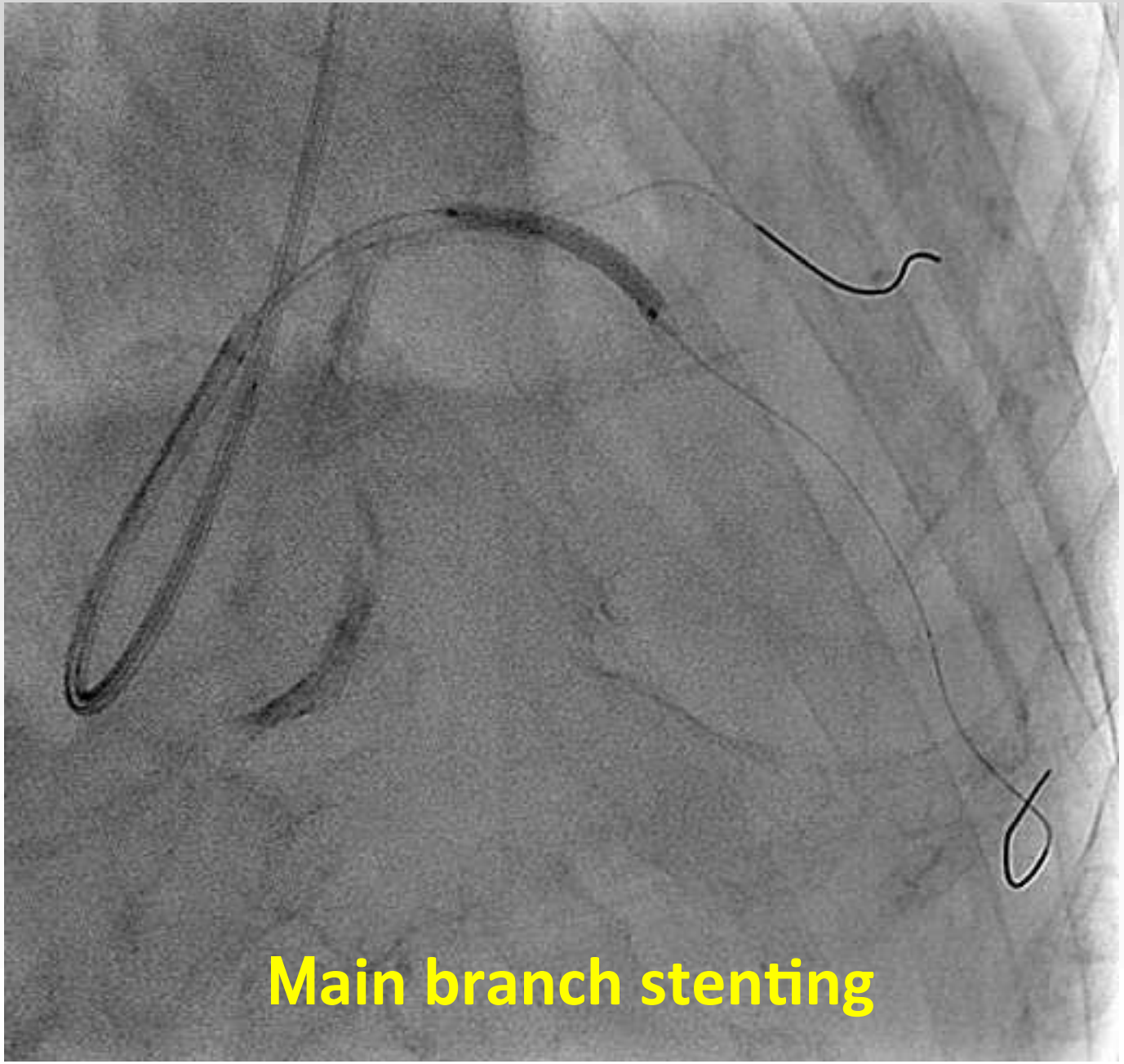
Main branch stenting

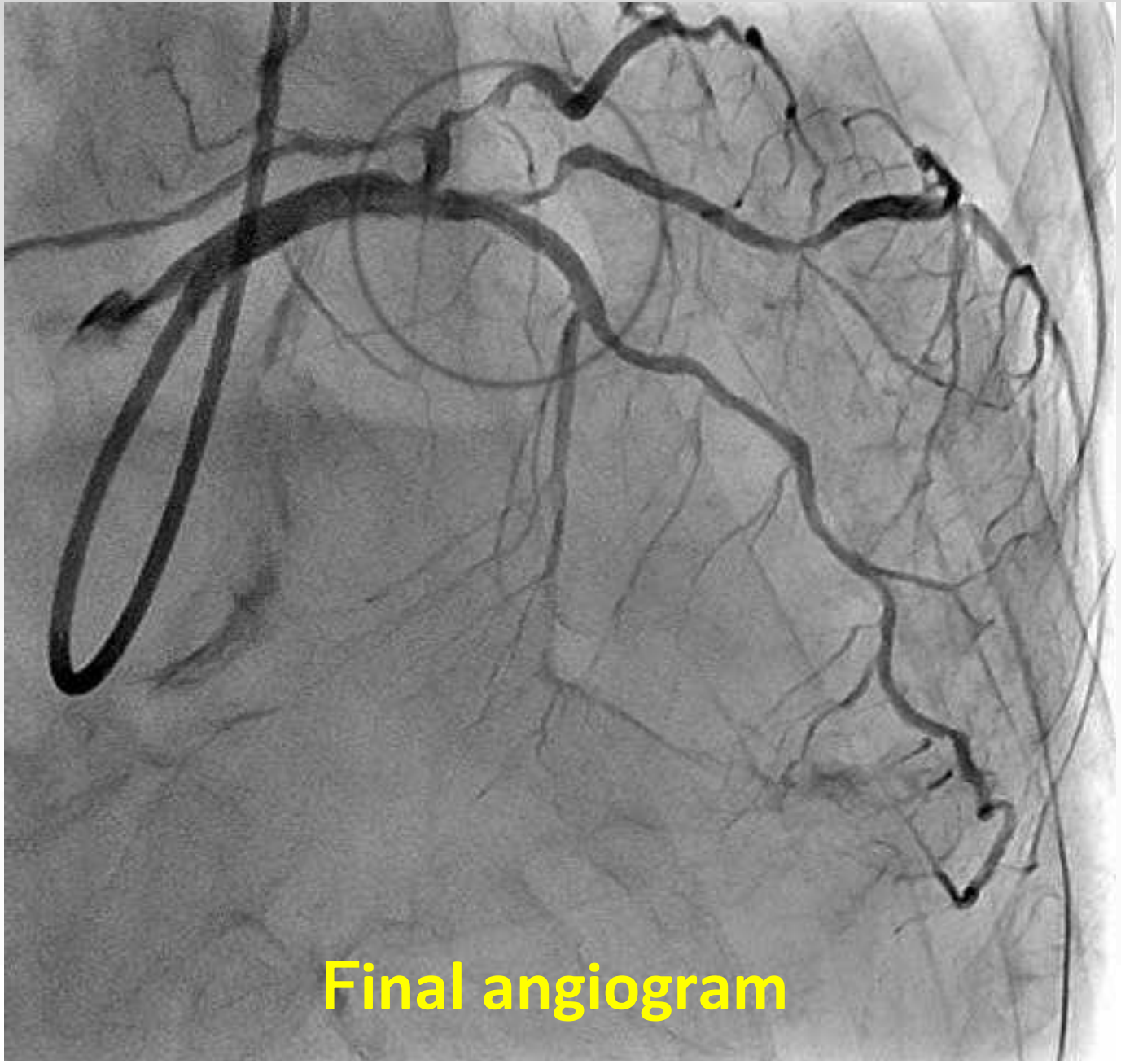
Final angiogram

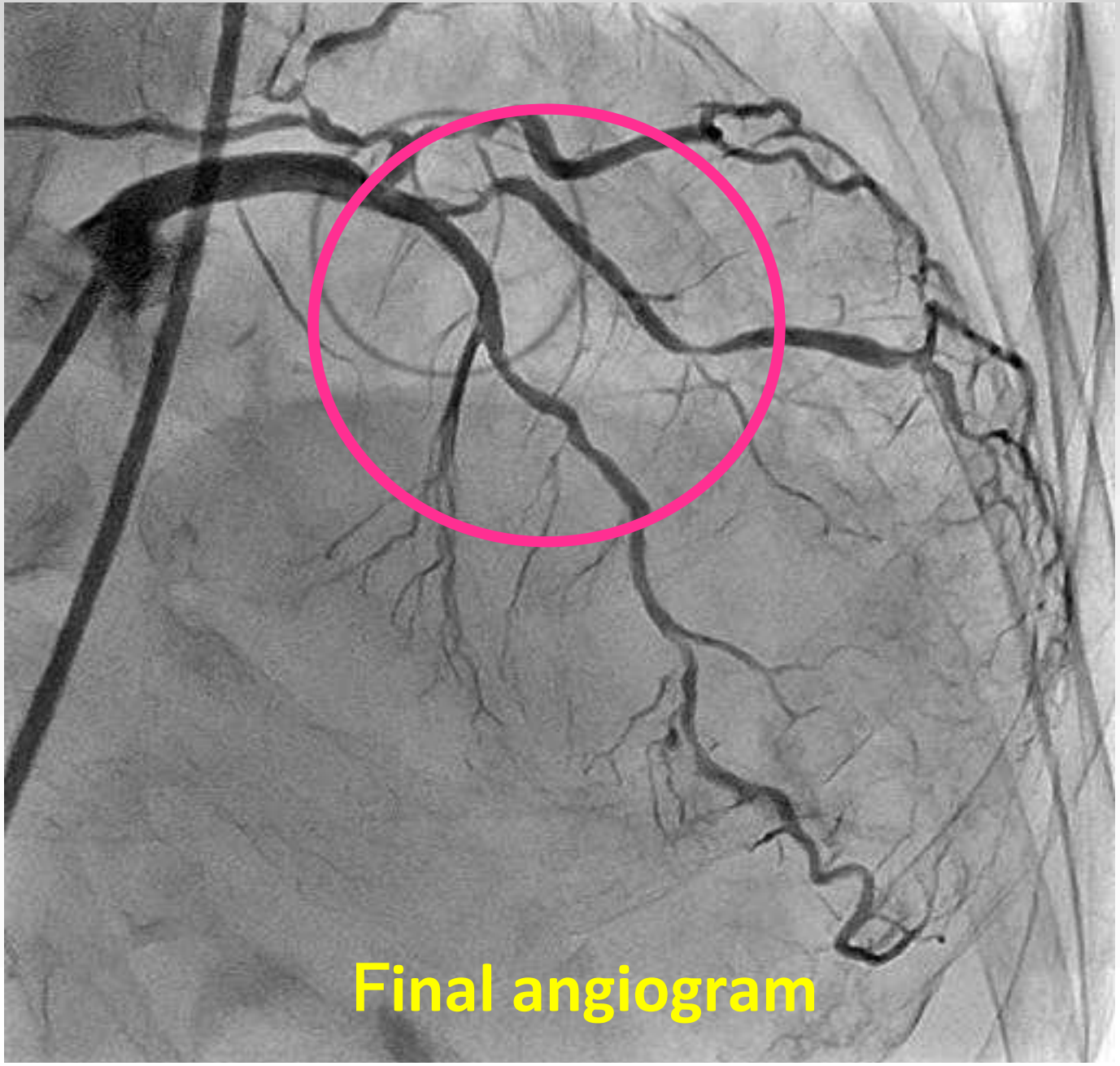
Final angiogram

case3


Image size: 512 x 512
WL: 128 WW: 256
332357 (77 y , 76 y)
Pci
1Coronaries
Zoom: 296%
Im: 41/94 Series: 1
JPEGLossless:Non-hierarchical-1stOrderPrediction
2015/05/27 15:08:41
Made In OsiriX

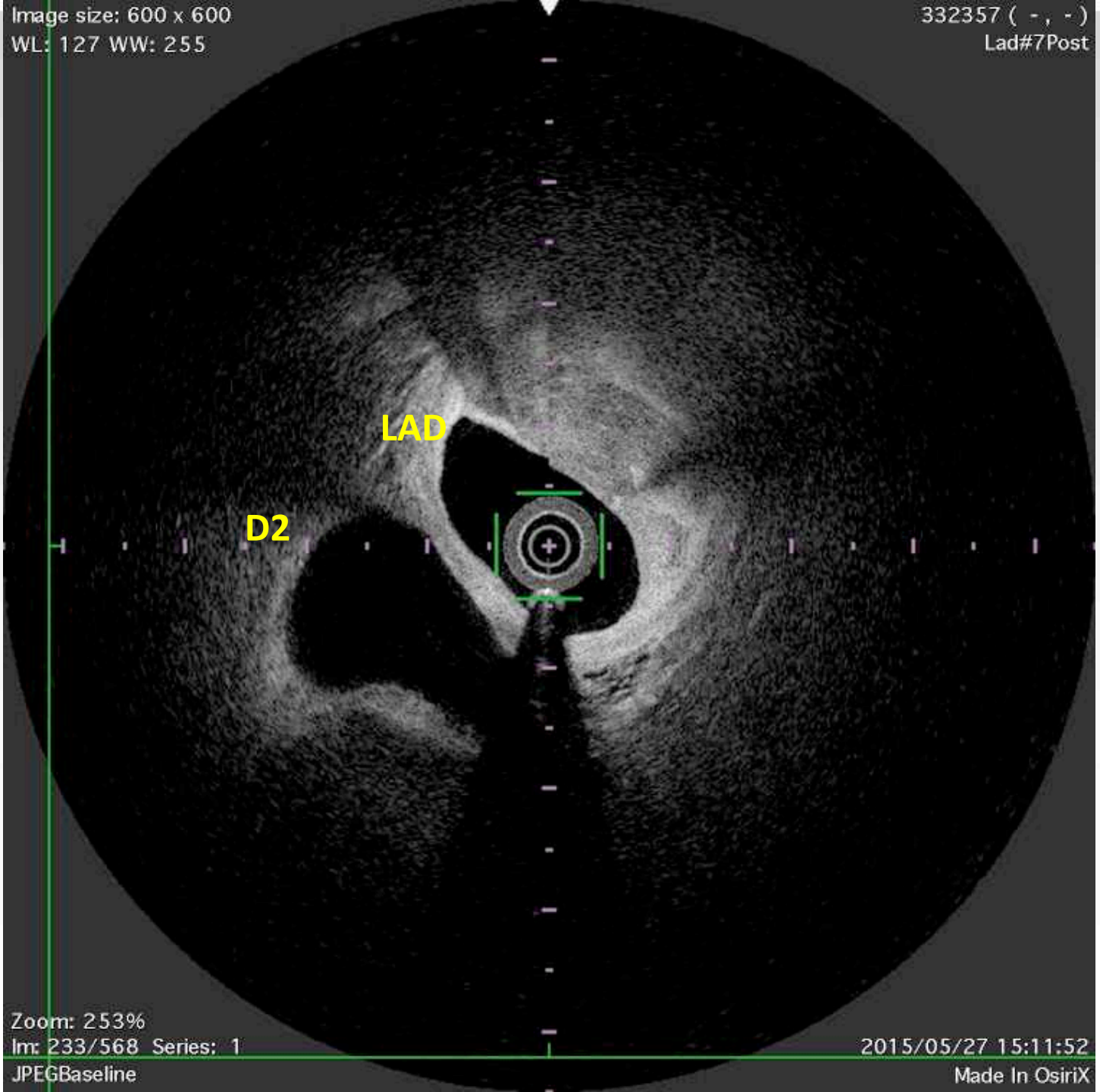
Image size: 600 x 600
WL: 127 WW: 255
332357 (-, -)
Lad#7Post
LAD
D2
Zoom: 253%
Im: 233/568 Series: 1
2015/05/27 15:11:52
JPEGBaseline
Made In OsiriX


Image size: 512 x 512
WL: 128 WW: 256
332357 (77 y , 76 y)
Pci
1Coronaries
Zoom: 296%
Im: 28/384 Series: 1
JPEGLossless:Non-hierarchical-1stOrderPrediction
2015/05/27 16:02:44
Made In OsiriX

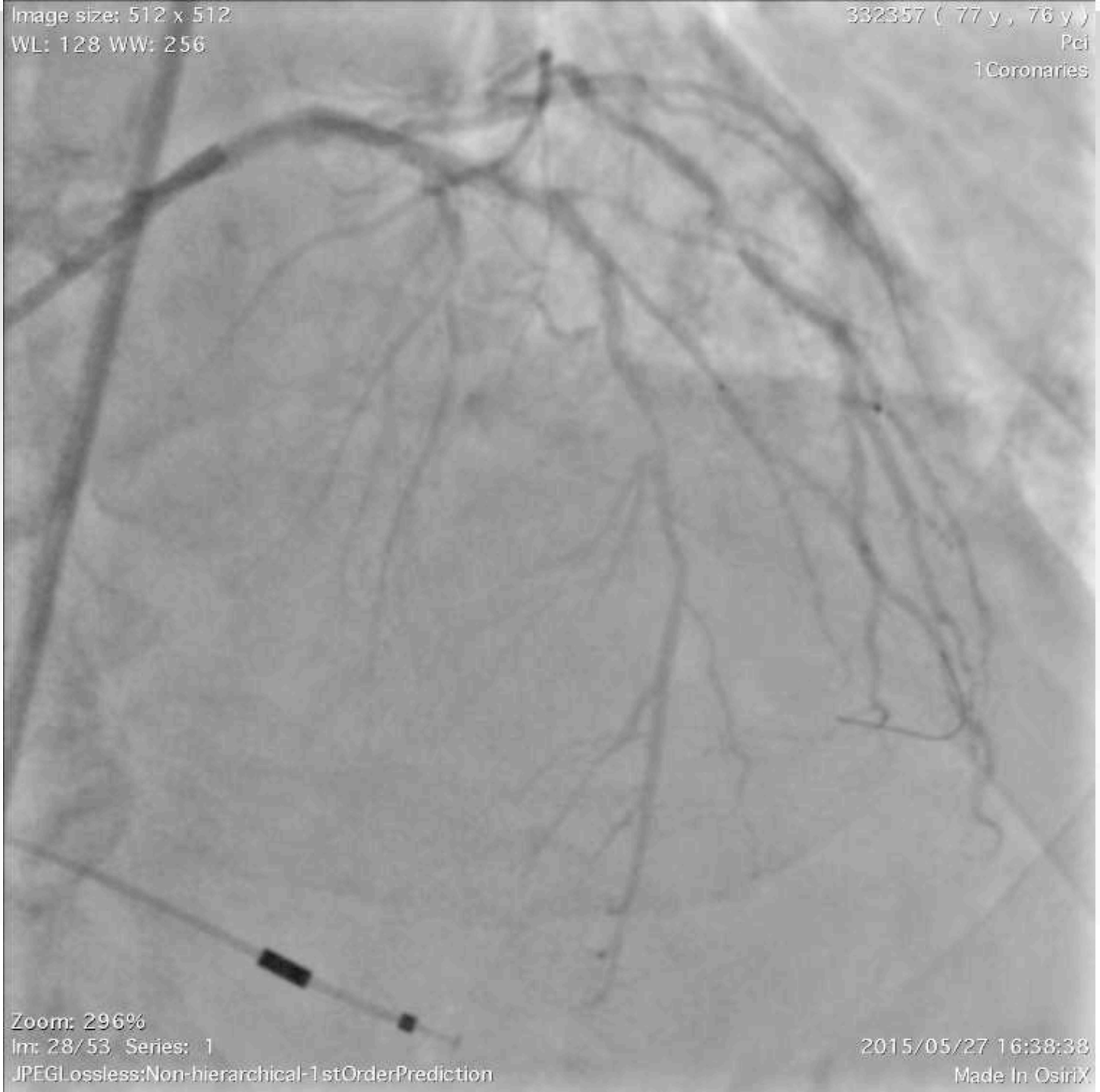
Image size: 512 x 512
WL: 128 WW: 256
332357 (77 y , 76 y)
Pci
1Coronaries
Zoom: 296%
Im: 28/53 Series: 1
JPEGLossless:Non-hierarchical-1stOrderPrediction
2015/05/27 16:38:38
Made In OsiriX

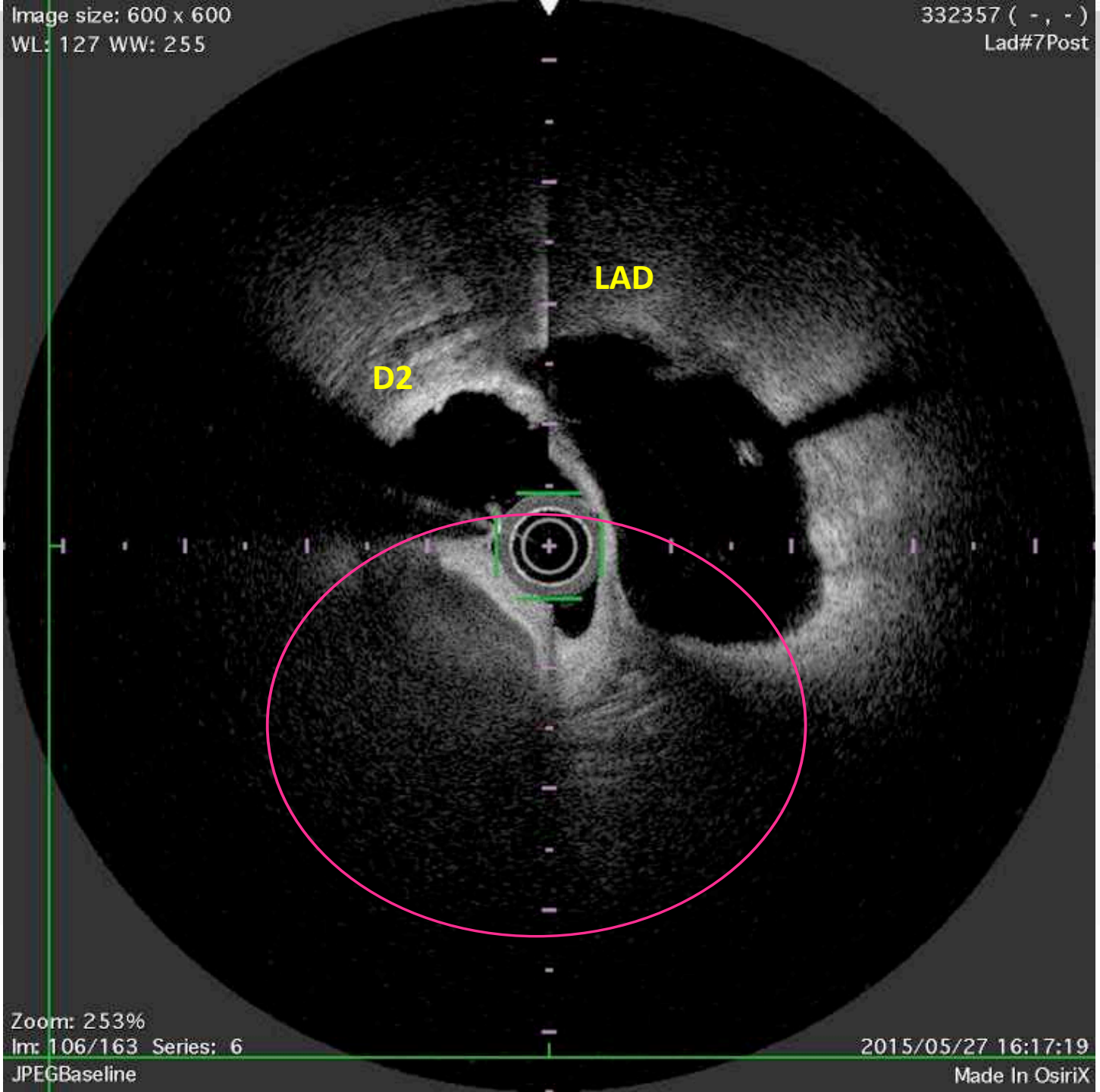
Image size: 600 x 600
WL: 127 WW: 255
332357 (-, -)
Lad#7Post
LAD
D2
Zoom: 253%
Im: 106/163 Series: 6
2015/05/27 16:17:19
JPEGBaseline
Made In OsiriX


Image size: 512 x 512
WL: 128 WW: 256
332357 (77 y , 76 y)
Pci
1Coronaries
Zoom: 296%
Im: 41/205 Series: 1
JPEGLossless:Non-hierarchical-1stOrderPrediction
2015/05/27 16:35:13
Made In OsiriX


Image size: 512 x 512
WL: 128 WW: 256
332357 (77 y , 76 y)
Pci
1Coronaries
Zoom: 296%
Im: 24/80 Series: 1
JPEGLossless:Non-hierarchical-1stOrderPrediction
2015/05/27 16:46:51
Made In OsiriX

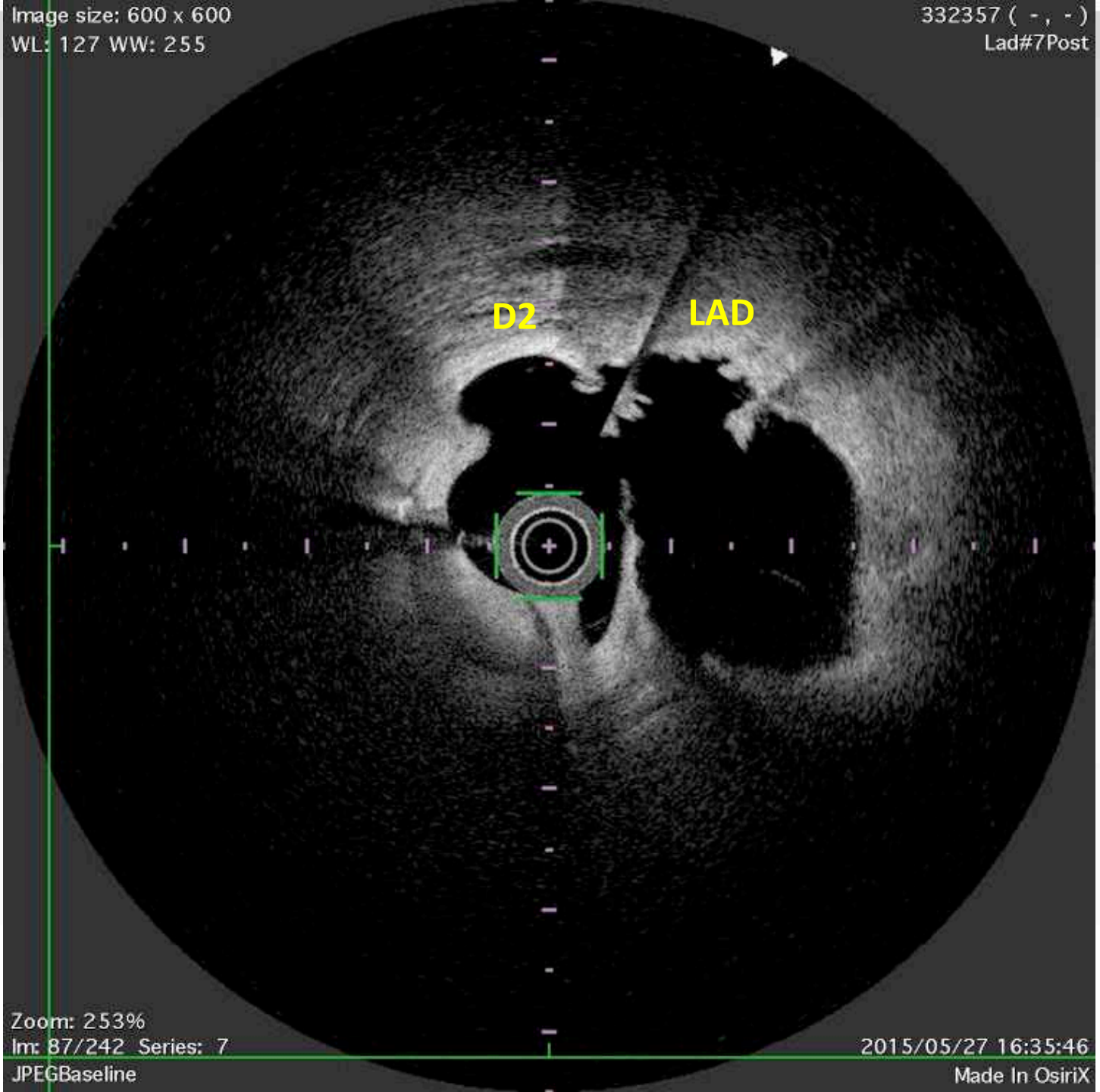
Image size: 600 x 600
WL: 127 WW: 255
332357 (- , -)
Lad#7Post
D2
LAD
Zoom: 253%
Im: 87/242 Series: 7
2015/05/27 16:35:46
JPEGBaseline
Made In OsiriX

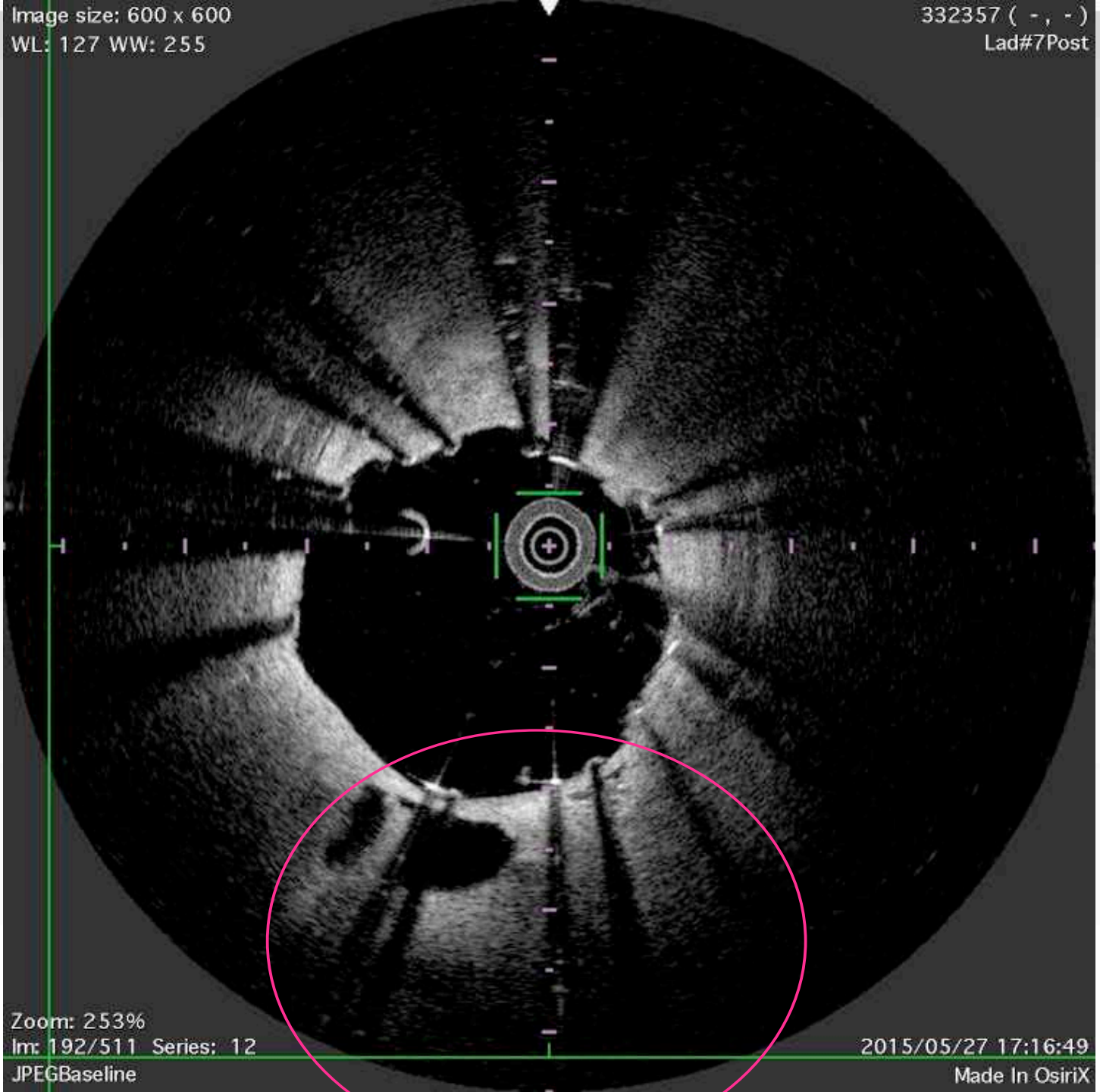
Image size: 600 x 600
WL: 127 WW: 255
332357 (-, -)
Lad#7Post
Zoom: 253%
Im: 192/511 Series: 12
2015/05/27 17:16:49
JPEGBaseline
Made In OsiriX


Image size: 512 x 512
WL: 128 WW: 256
332357 (77 y , 76 y)
Pci
1Coronaries
Zoom: 296%
Im: 37/100 Series: 1
JPEGLossless:Non-hierarchical-1stOrderPrediction
2015/05/27 17:21:29
Made In OsiriX

case 4

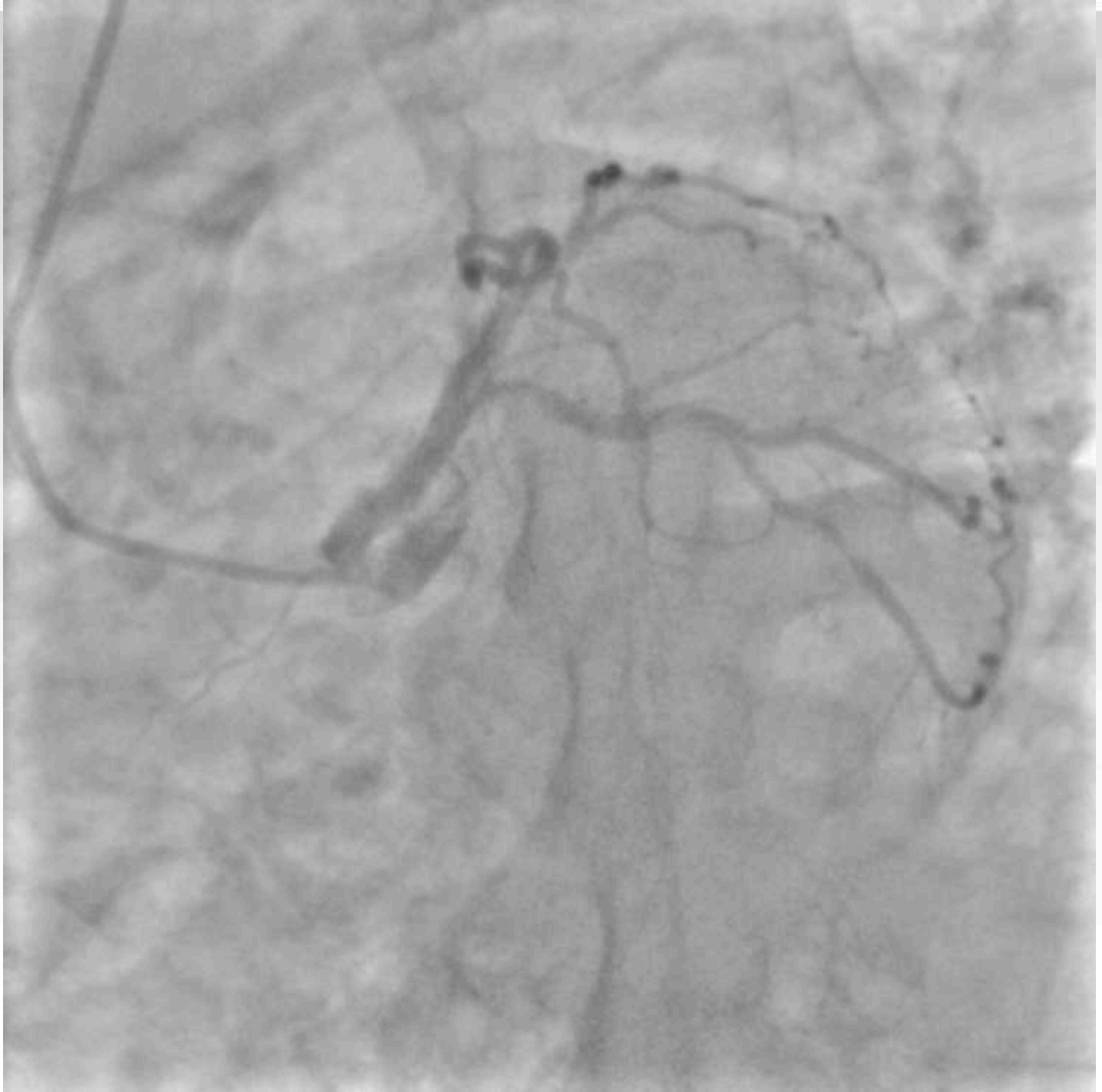

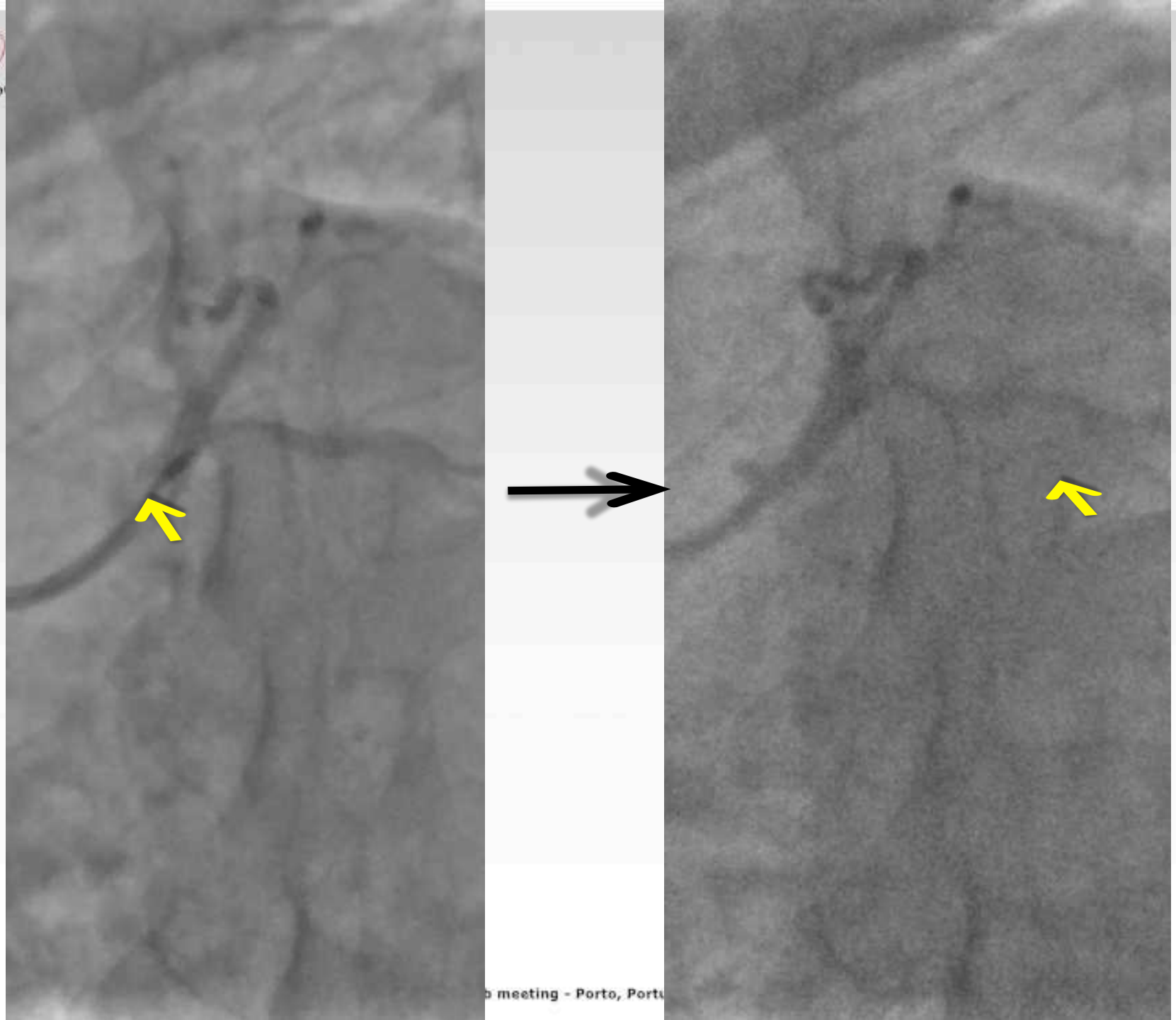

case 5

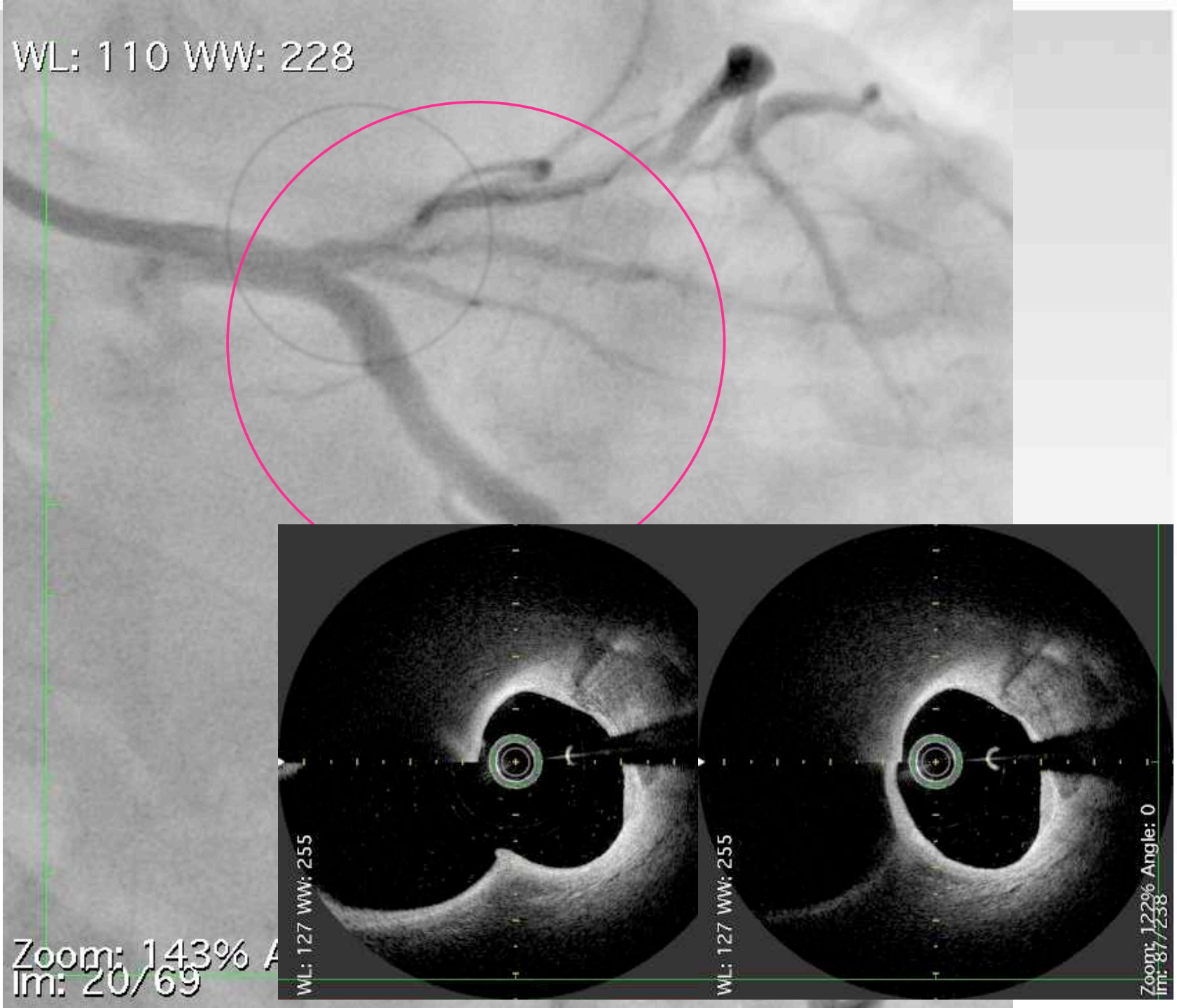
WL: 110 WW: 228
Zoom: 143% A
Im: 20/69
WL: 127 WW: 255
WL: 127 WW: 255
Zoom: 122% Angle: 0
Im: 87/238

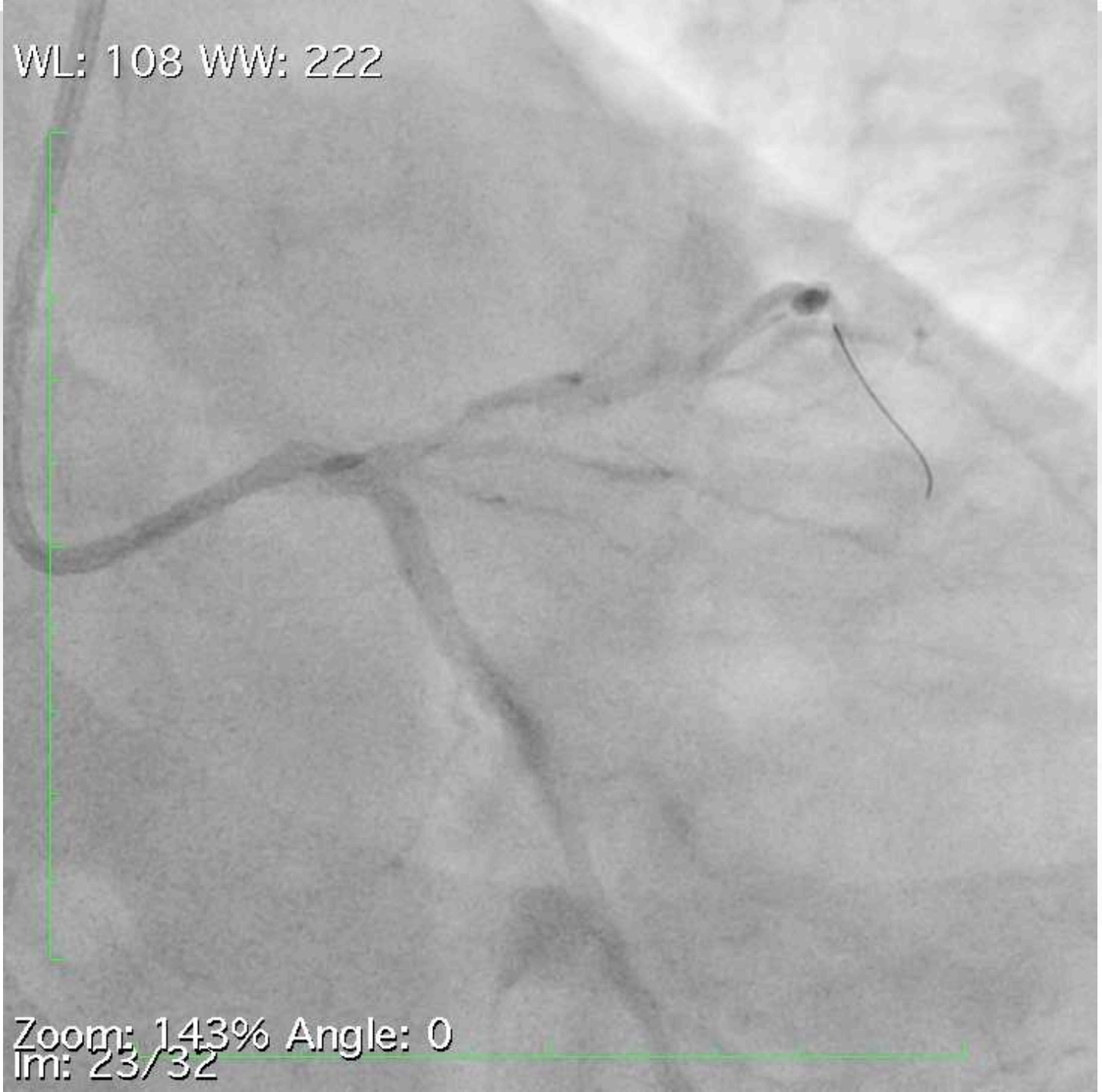
WL: 108 WW: 222
Zoom: 143% Angle: 0
Im: 23/32

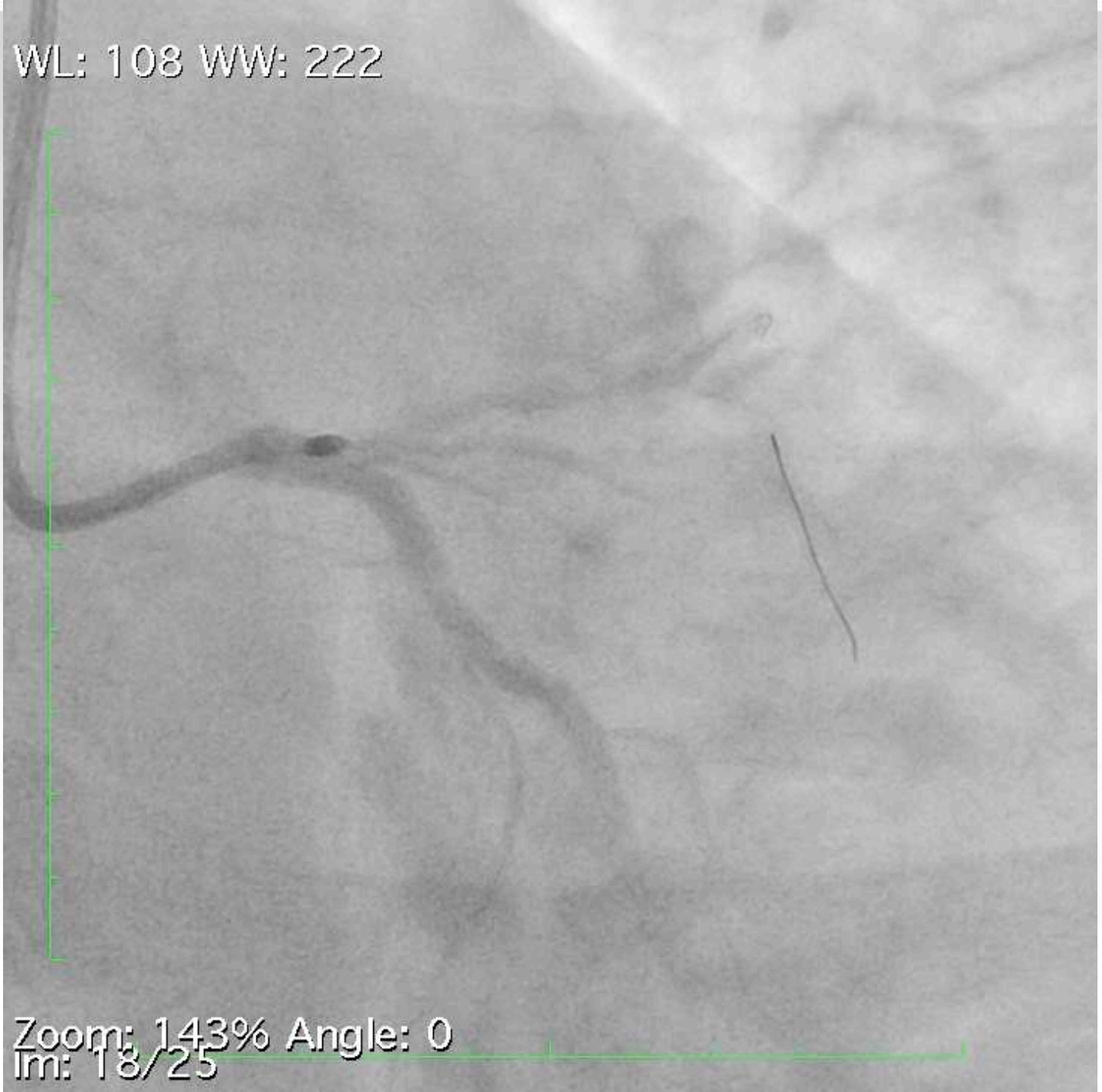
WL: 108 WW: 222
Zoom: 143% Angle: 0
Im: 18/25

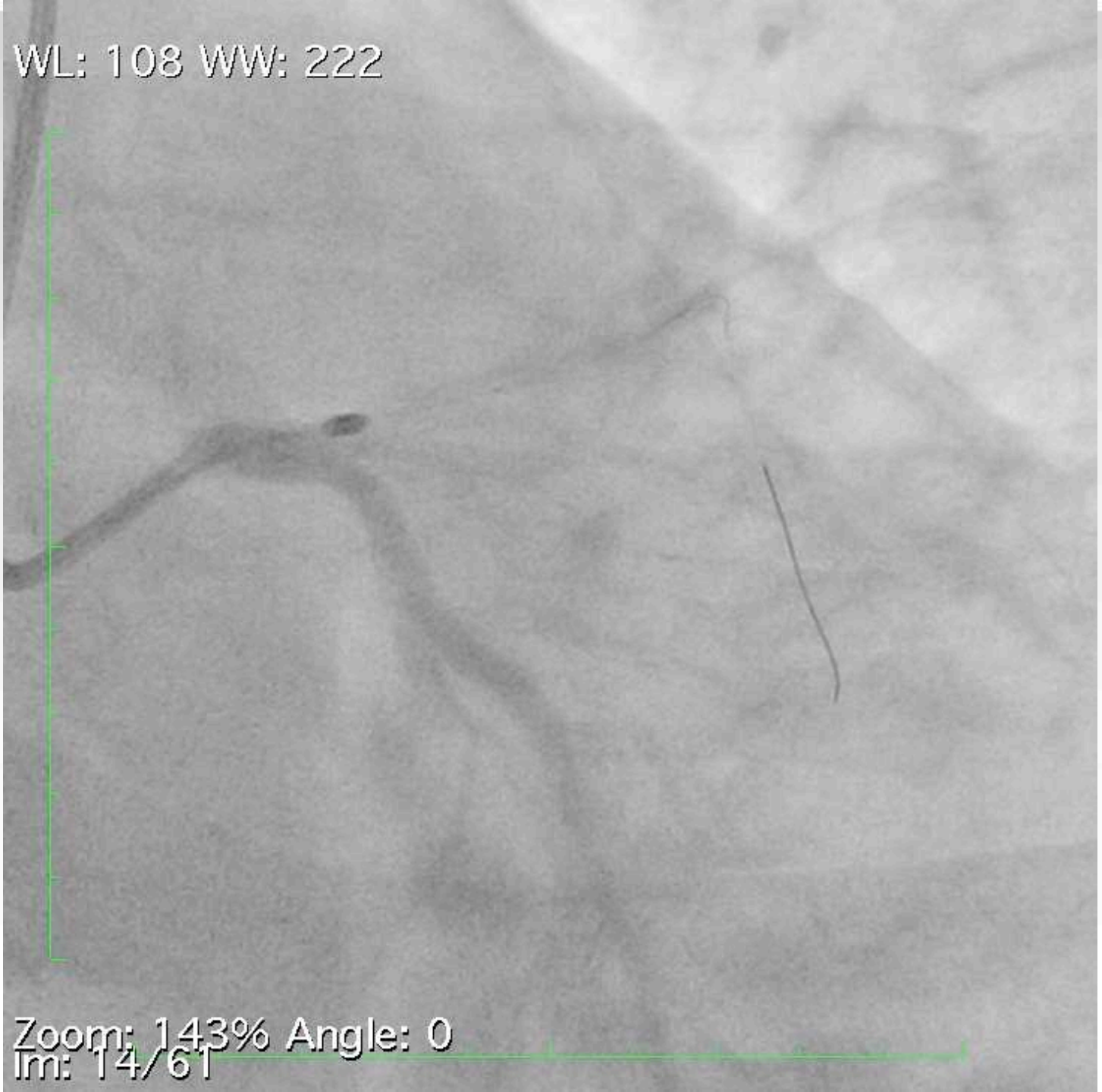
WL: 108 WW: 222
Zoom: 143% Angle: 0
Im: 14/61

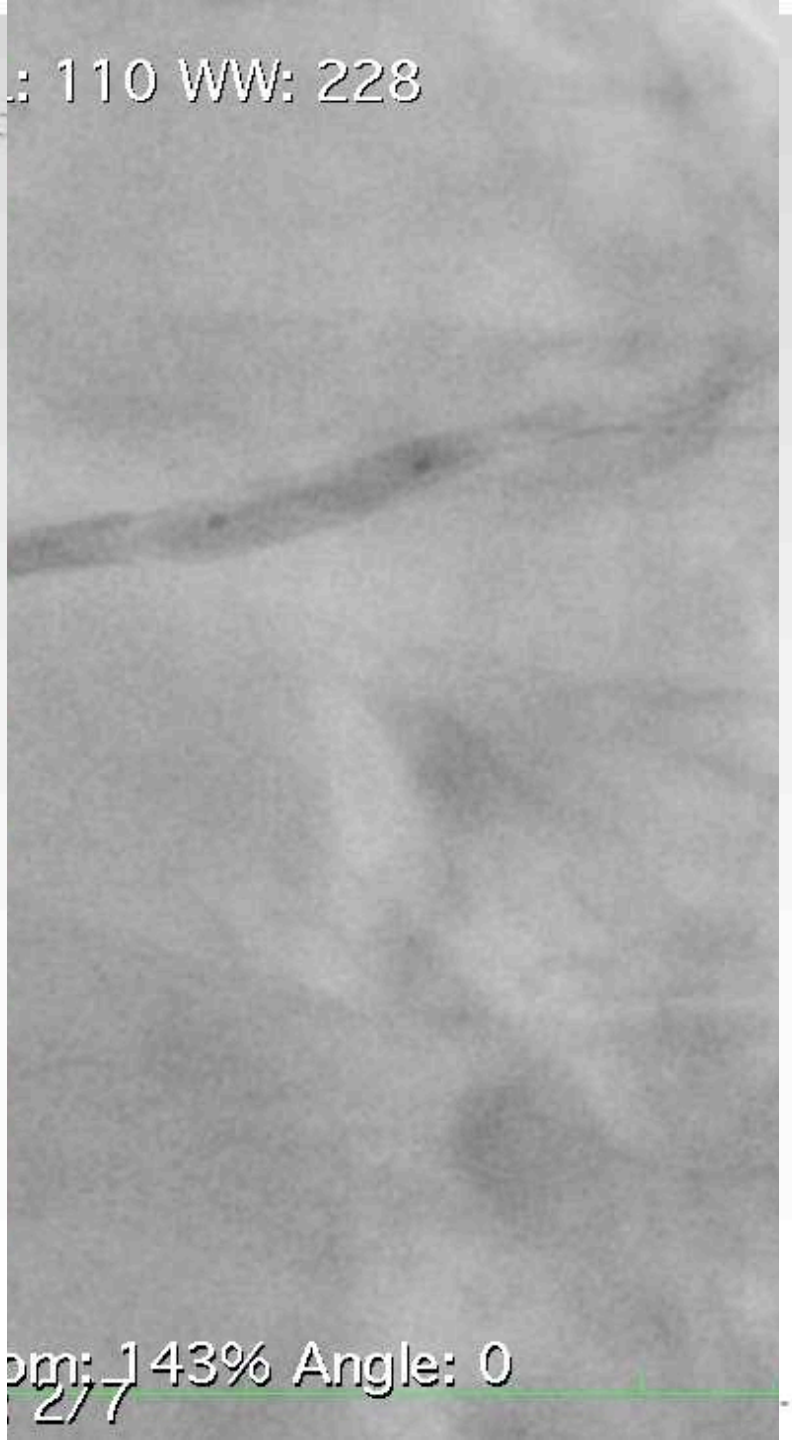
L: 110 WW: 228
om: 143% Angle: 0
2/7

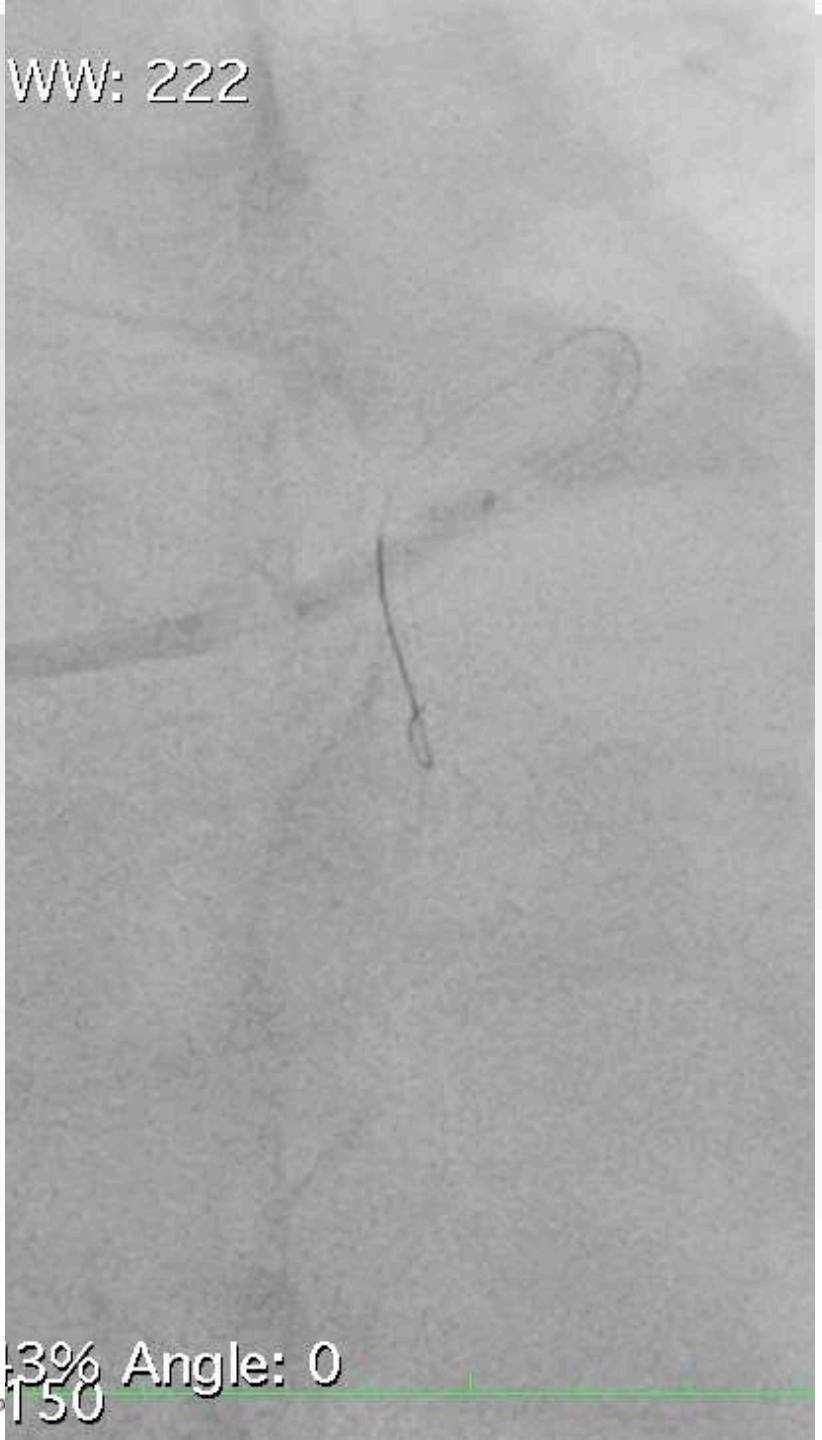
WW: 222
3% Angle: 0
150


WL: 110 WW: 228
Zoom: 143% Angle: 0
Im: 46/107

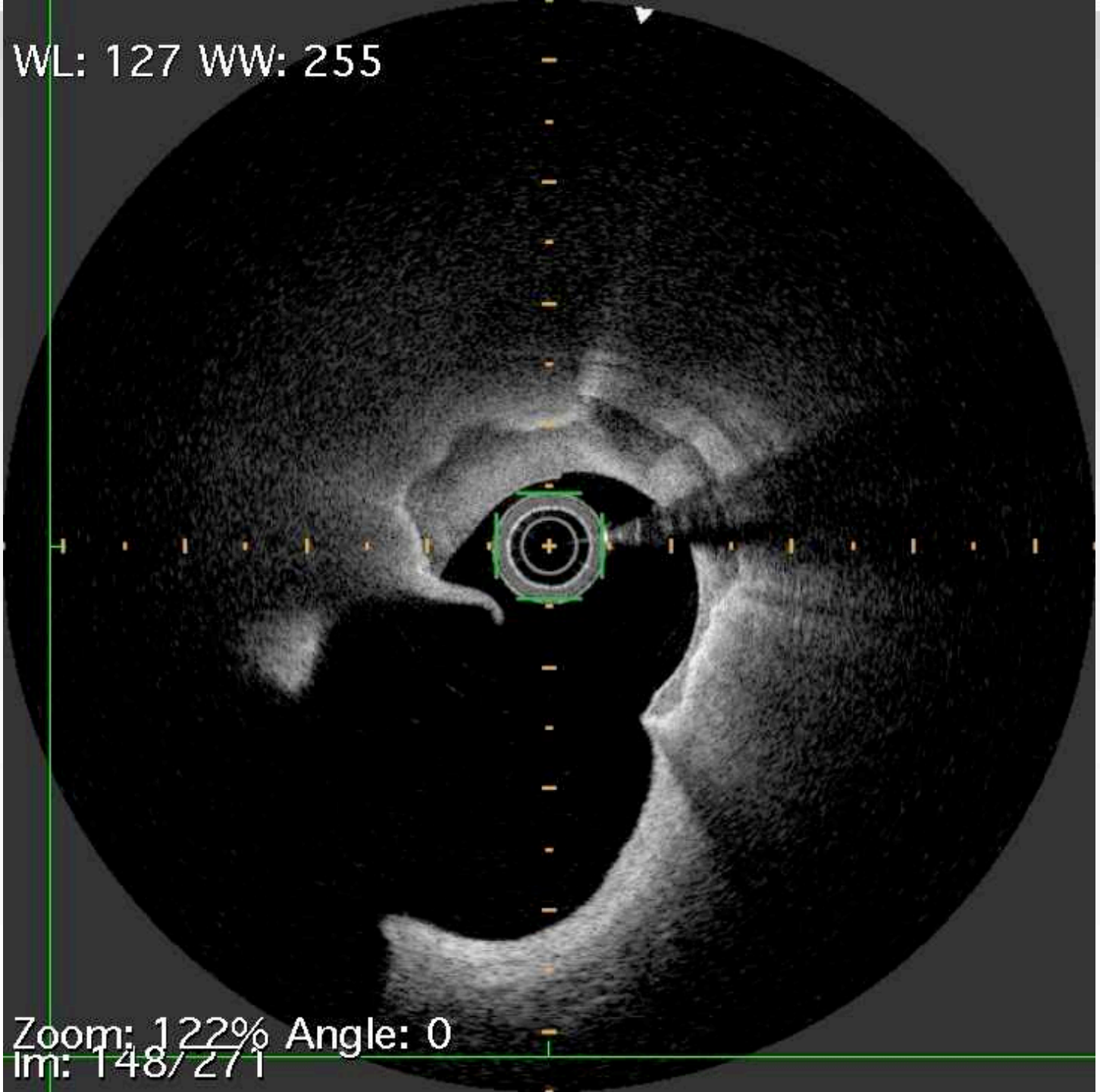
WL: 127 WW: 255
Zoom: 122% Angle: 0
Im: 148/271

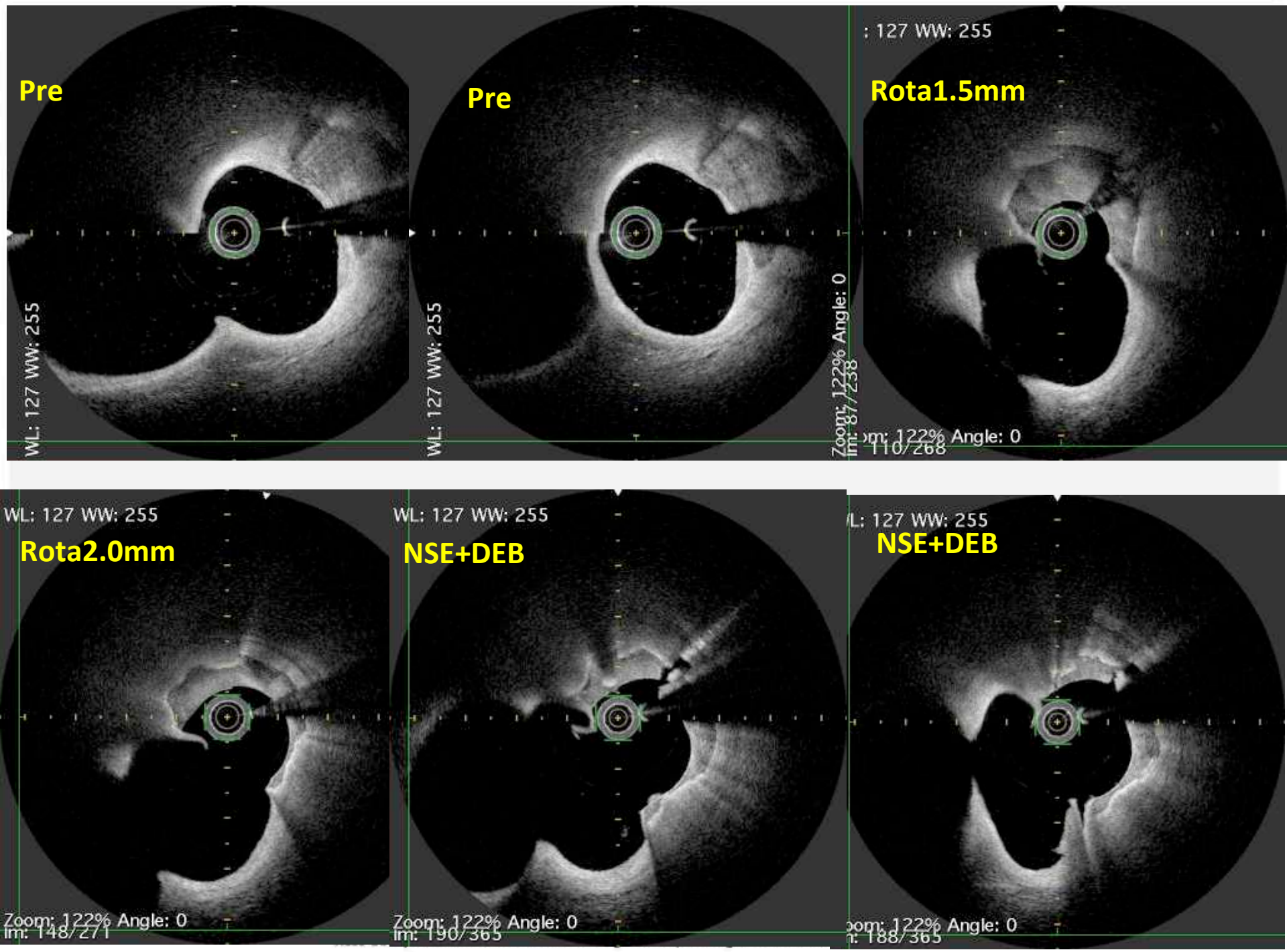
Pre
WL: 127 WW: 255
Pre
WL: 127 WW: 255
Zoom: 122% Angle: 0
Im: 87/238
: 127 WW: 255
Rota1.5mm
Zoom: 122% Angle: 0
Im: 110/268
WL: 127 WW: 255
Rota2.0mm
Zoom: 122% Angle: 0
Im: 148/271
WL: 127 WW: 255
NSE+DEB
Zoom: 122% Angle: 0
Im: 190/365
WL: 127 WW: 255
NSE+DEB
Zoom: 122% Angle: 0
Im: 188/365

SUMMARY

- Know plaque distribution
- Know carina shift
- Know wire bias
- Appropriate debulking (rotablation/DCA) may achieve good stent expansion but also reduce a chance of compromising of side branch and finally avoid complex stenting
- OCT/OFDI can identify the thickness of calcified plaque, so we can recognize the capacity of ablation of Rotablator in bifurcation site.
- OCT/OFDI is very useful imaging guidance for treatment bifurcation lesion, especially in lesion containing of hard and calcified plaque using Rotablator

Thank you