



DK-miniCrush Left Main Bifurcation Lesions



Qingdao Municipal Hospital

Dr. Zhengzhong Wang



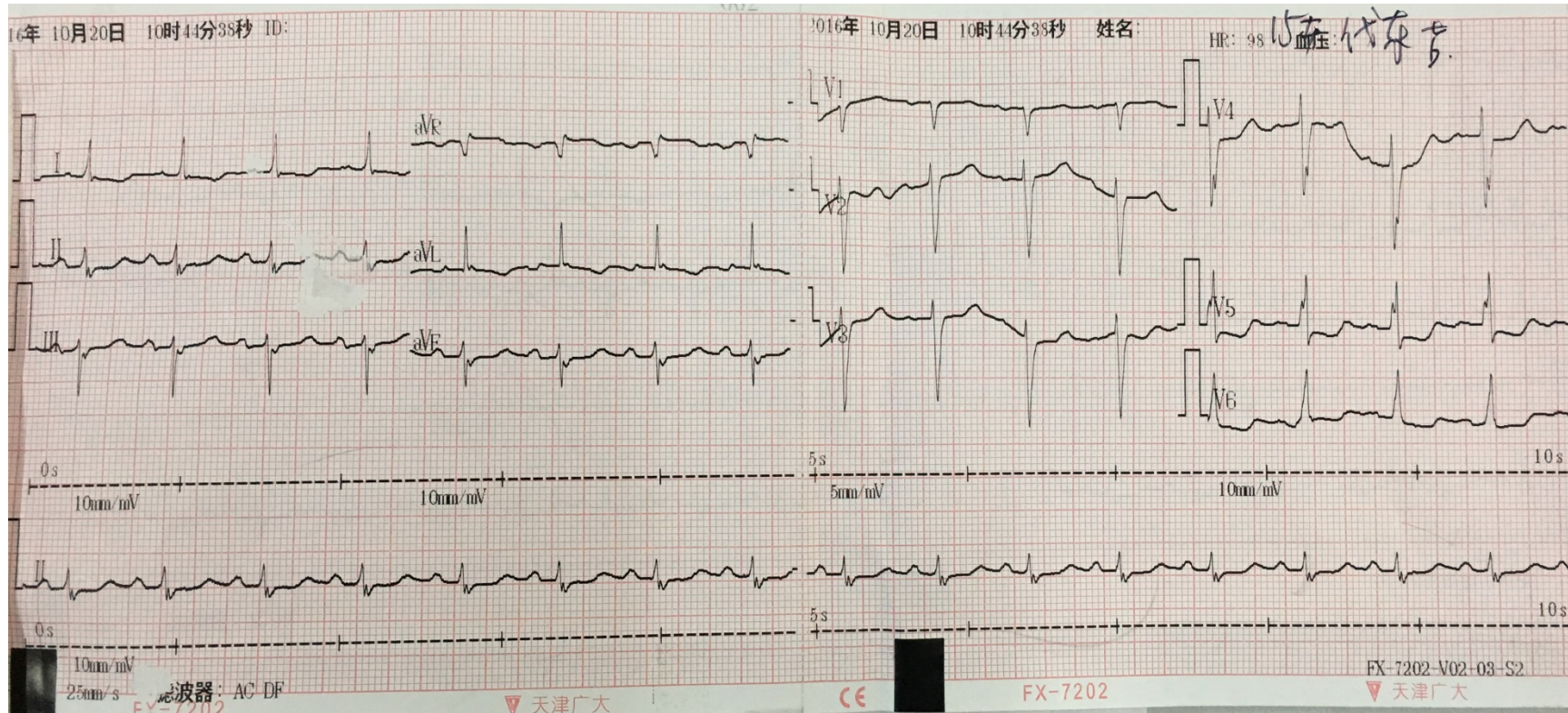
青島市市立醫院(集團)
QINGDAO MUNICIPAL HOSPITAL (GROUP)

生命綠洲
王洲頌敬書

Cases 1

- Male, 64 years old
- Complaint: Paroxysmal chest pain, chest tightness for 4 years , aggravated for 3 days
- Past history : 3 stents in LAD 4 years ago, DM 11years; Smoking **40 years**

ECG



Echocardiogram

超声数值:

	二维及 M 超			频谱多普勒	
升主动脉	27 mm	主动脉窦	30 mm	主动脉瓣流速	1.0 m/s
主动脉瓣环	21 mm	左房前后径	43 mm	三尖瓣压差	19 mmHg
左房左右径	43 mm	左房上下径	53 mm	二尖瓣E峰	1.1 m/s
室间隔	10.5 mm	左室前后径	58 mm	二尖瓣A峰	0.3 m/s
左室后壁	9.3 mm	RVOT前后径	/ mm	DT时间	/ ms
右室左右径	43 mm	右房左右径	46 mm	二尖瓣环侧壁Em	/ cm/s
主肺动脉	24 mm	EF	39 %	二尖瓣环间隔Em	/ cm/s

超声描述:

声窗差, 结果供参考。

全心大, 左室后壁下段、下壁心尖段及室间隔中下段厚度变薄, 室间隔回声稍强, 以上室壁动度及增厚率减低, 余室壁厚度回声可, 动度及增厚率亦减低。主动脉瓣为三叶瓣, 局限性增厚, 回声增强, 启闭可, 余瓣膜形态、结构、启闭运动未见明显异常。心包腔未见异常。

多普勒检查: 舒张期二尖瓣前向血流E/A>2, 收缩期左、右房内探及少量反流信号。

CK及STI: 同上。

AQ: 左室舒张末容积增大, 每搏输出量减少。

TVI: 二尖瓣环运动Em=8.0cm/s, Am=3.0cm/s, Sm=5.0cm/s。

估测肺动脉收缩压正常。

超声提示:


节段性室壁运动异常

全心大

主动脉瓣退变

二、三尖瓣反流(轻度)

左心功能减低



Laboratory Examination

LDL 2.65 mmol/L, CTNI < 0.05 ng/ml,

BNP 1080 pg/ml, CR 98.68 μ mol/L

Diagnosis

1. CHD

Ischemic cardiomyopathy

OMI

POST-PCI

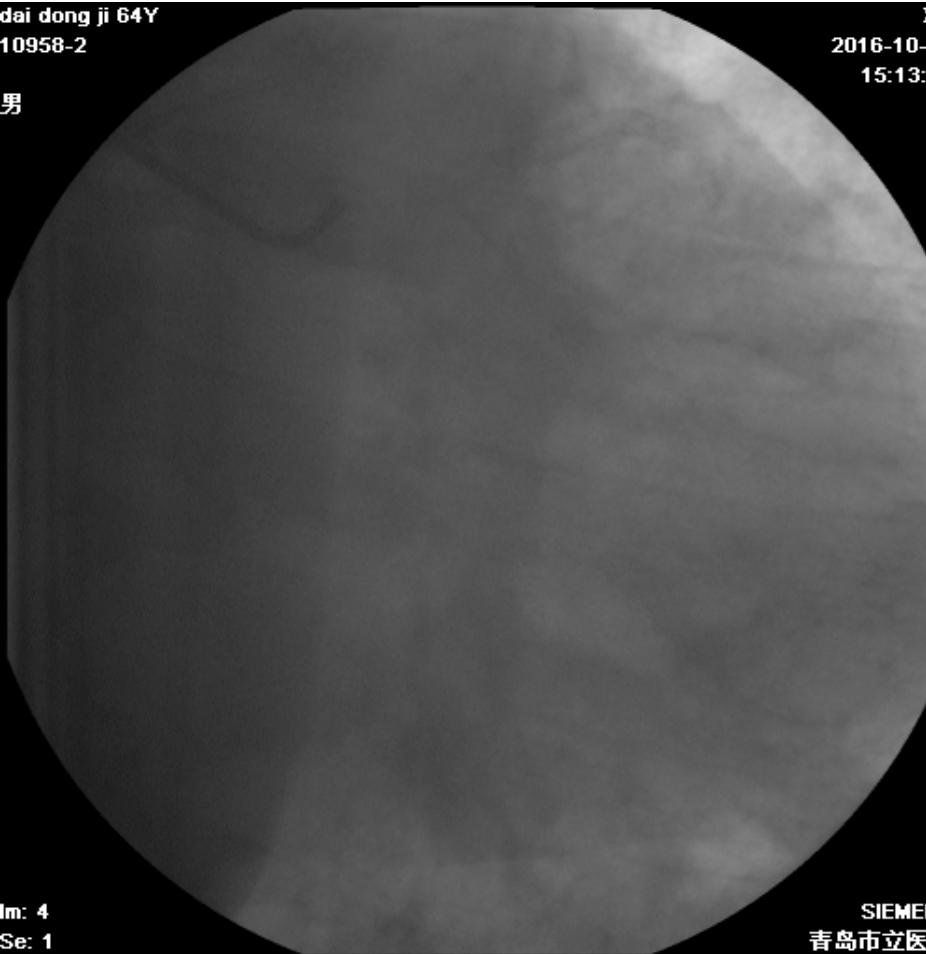
Cardiac function Grade III (NYHA)

2. Type-2 diabetes

CAG

dai dong ji 64Y
10958-2

男

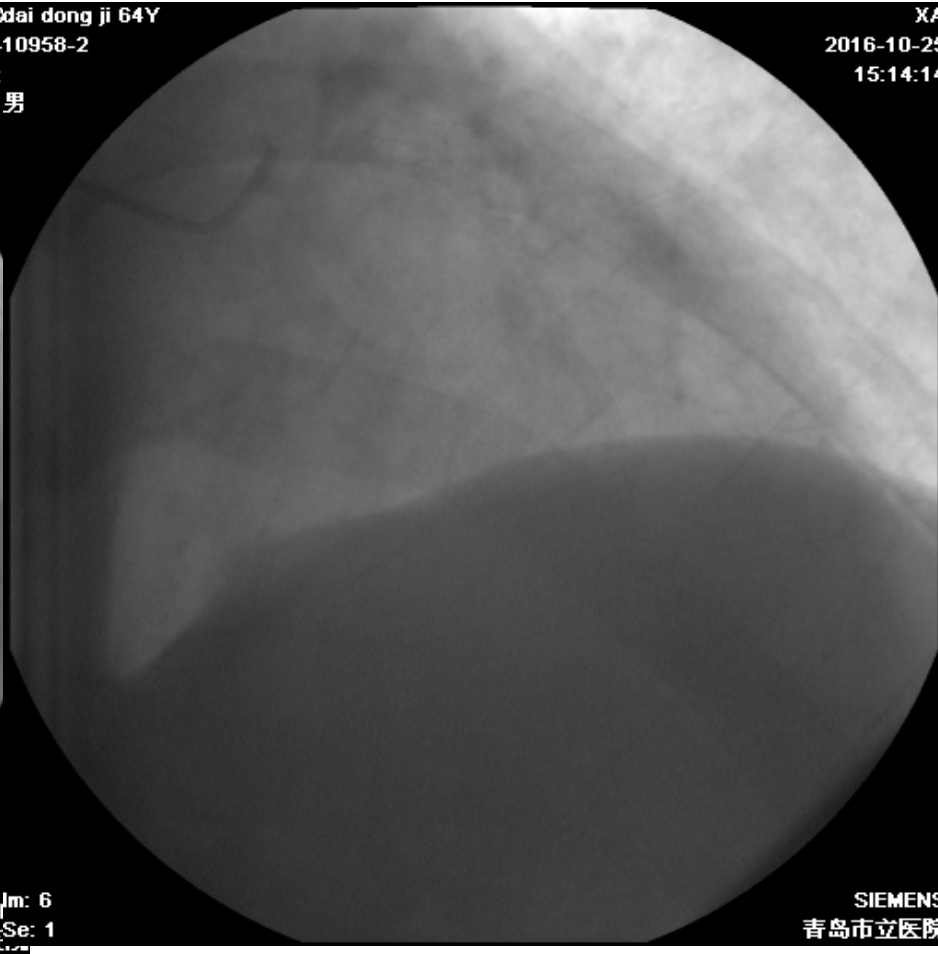


Im: 4
Se: 1

dai dong ji 64Y
2016-10-10958-2

15:13:

男



SIEMENS Im: 6
青島市立医院 Se: 1

XA
2016-10-25

15:14:14

SIEMENS
青島市立医院

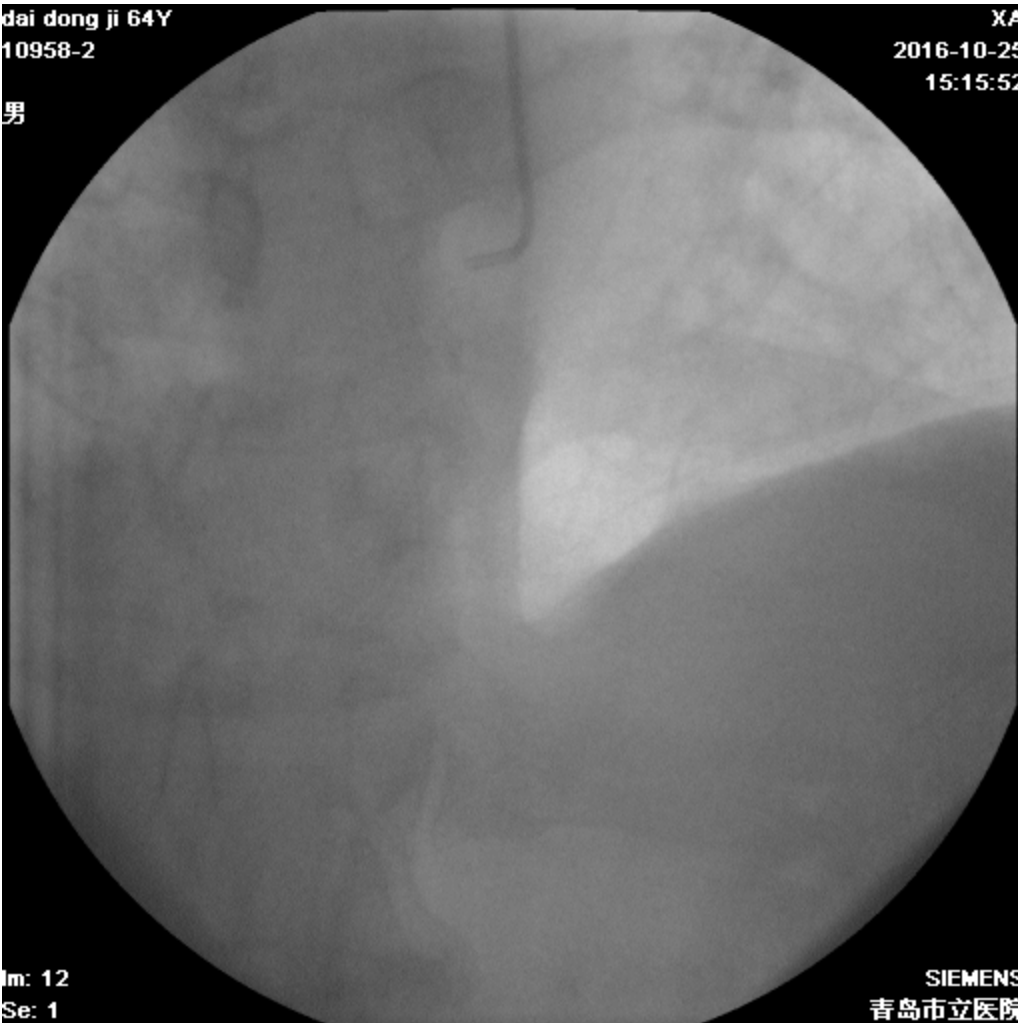
dai dong ji 64Y
10958-2

男

XA
2016-10-25
15:15:52

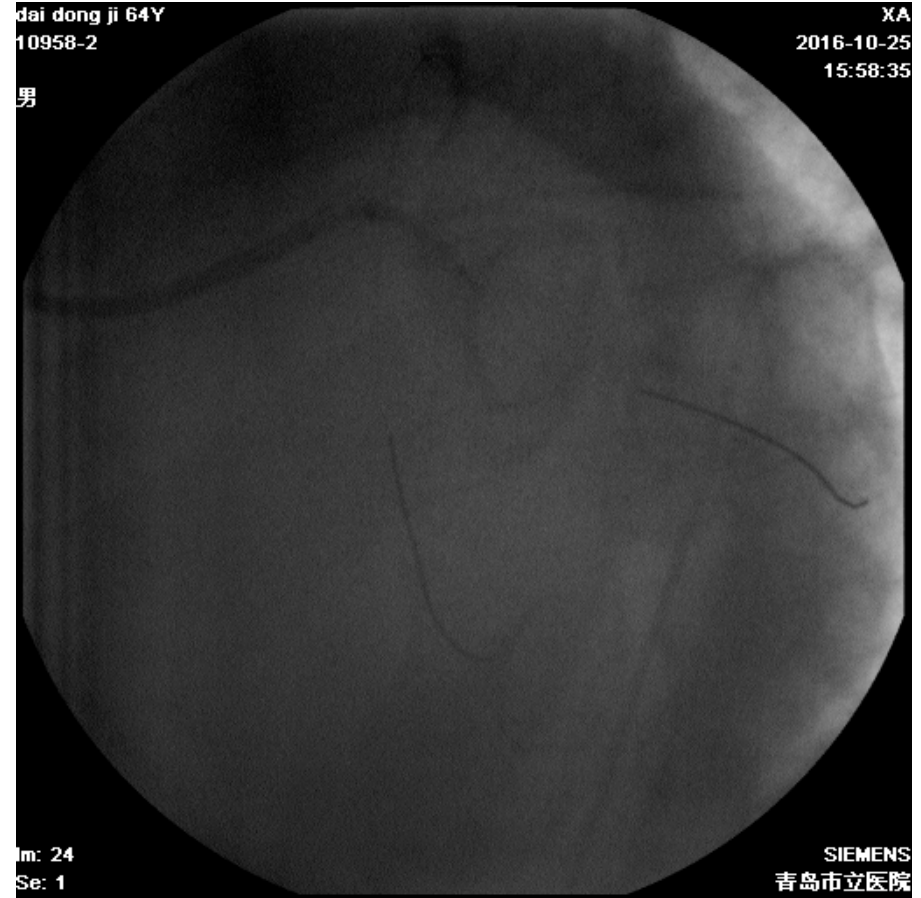
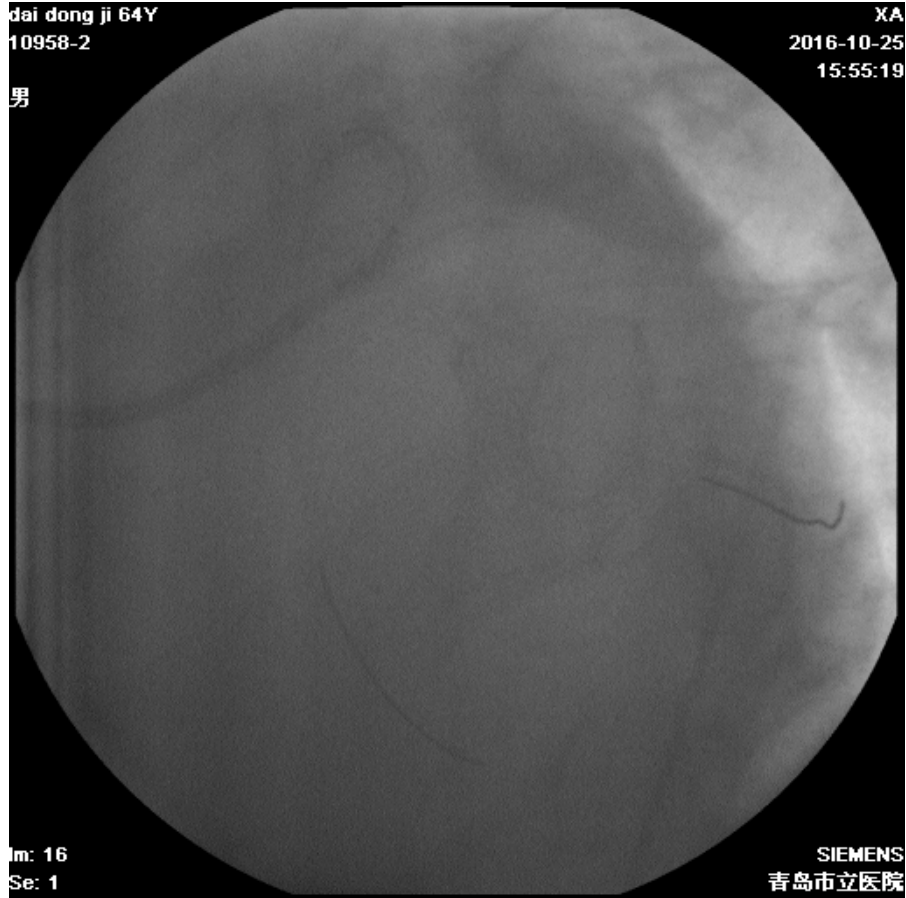
Im: 12
Se: 1

SIEMENS
青島市立医院



1.IABP+PCI

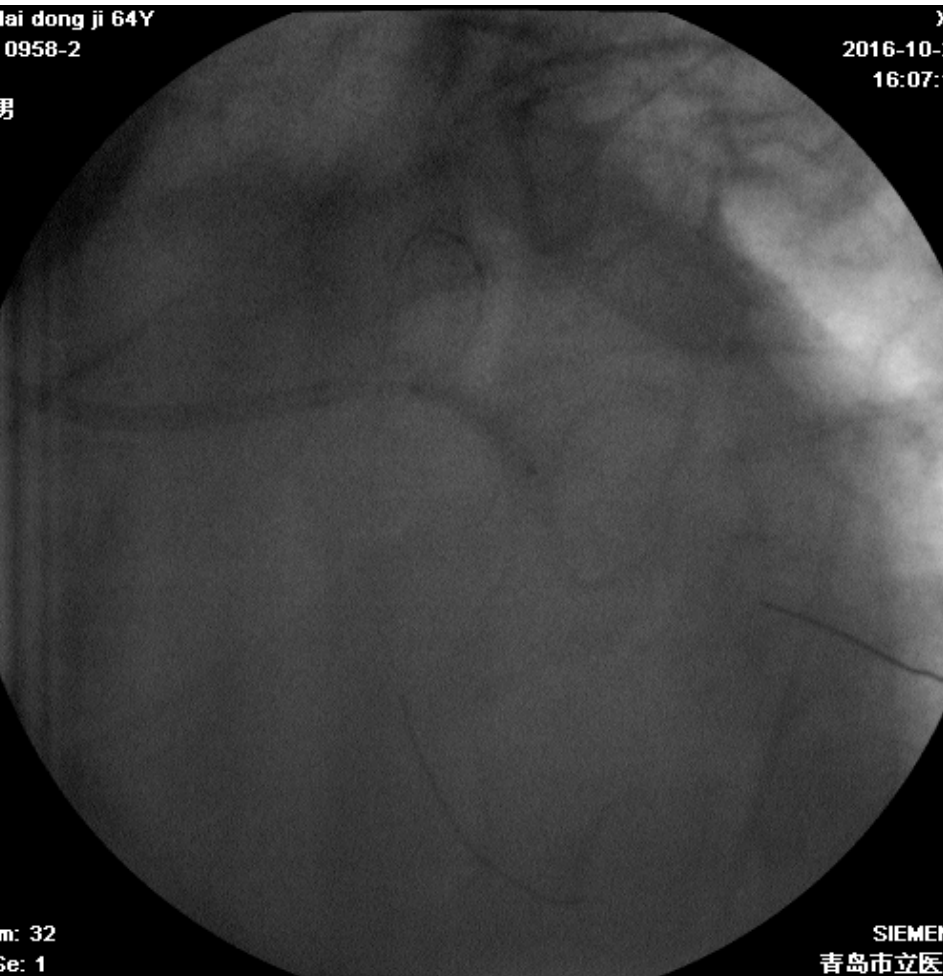
2.DK-miniCRUSH



6F EBU3.5 GC/Runthrough GW × 2/ 2.5*12mm SPRINTER BL

lai dong ji 64Y
0958-2

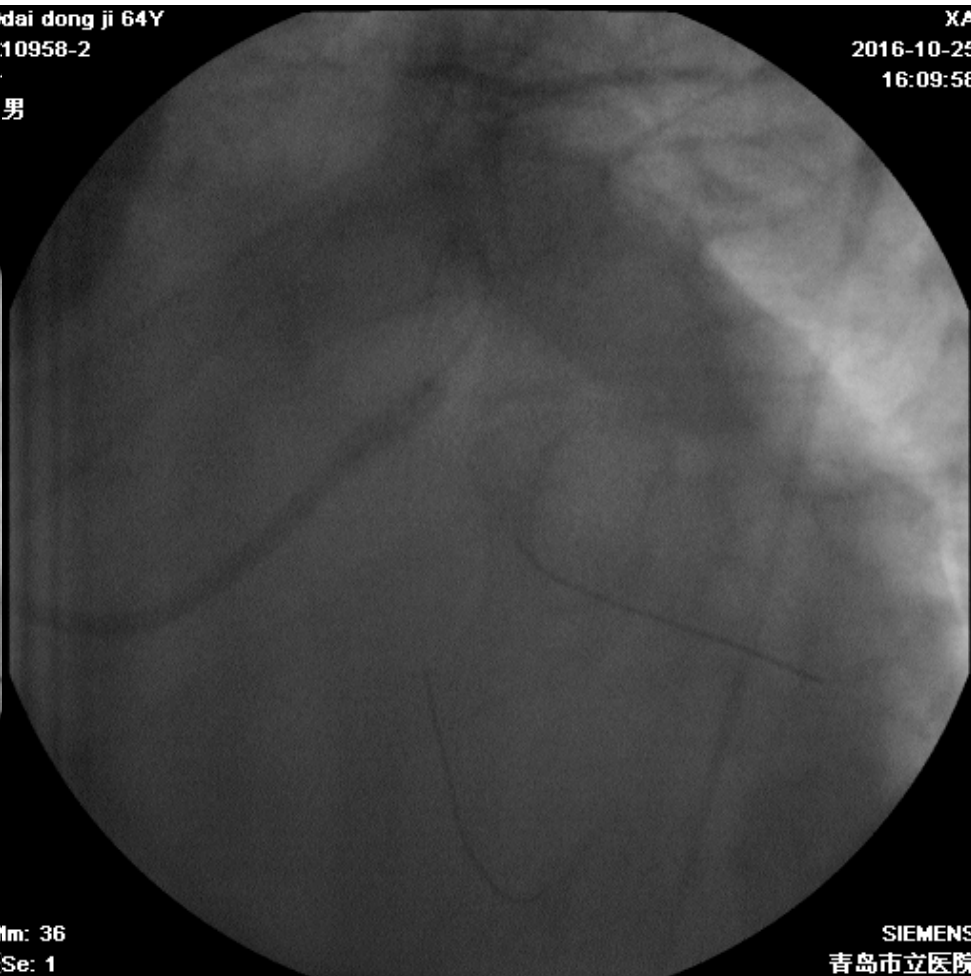
男



m: 32
Se: 1

lai dong ji 64Y
2016-10-10958-2
16:07:
男

SIEMENS
青島市立医院
Se: 1

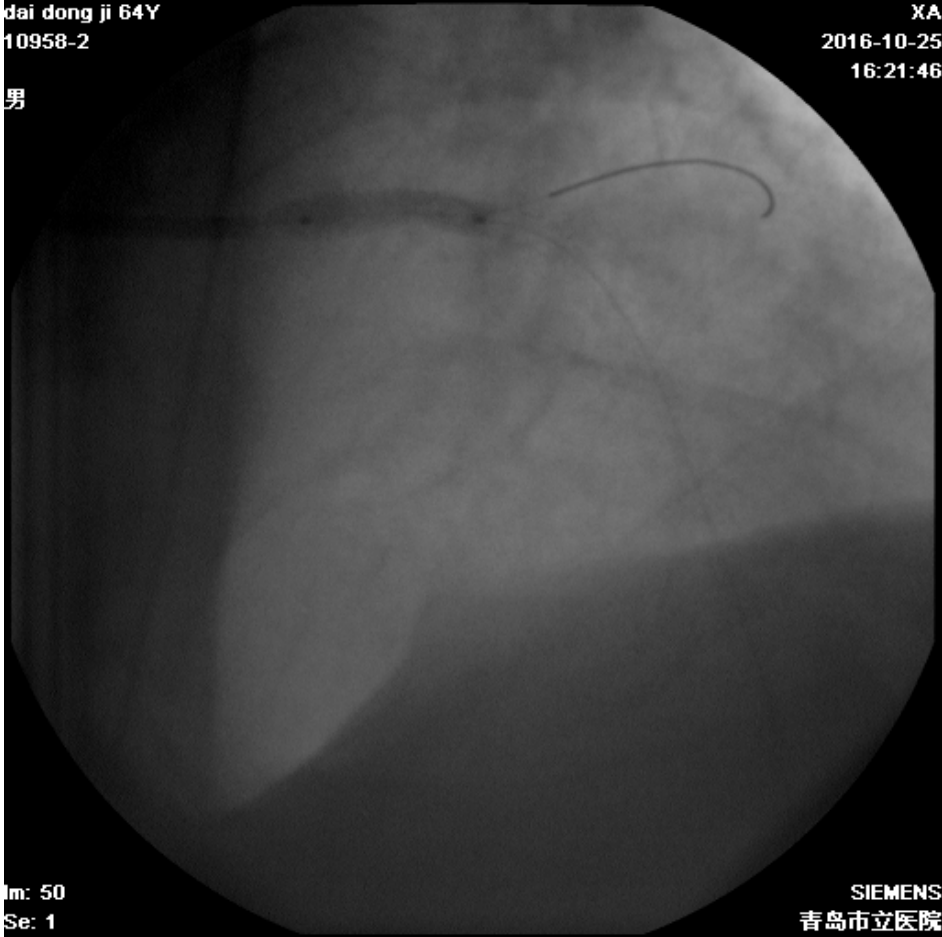
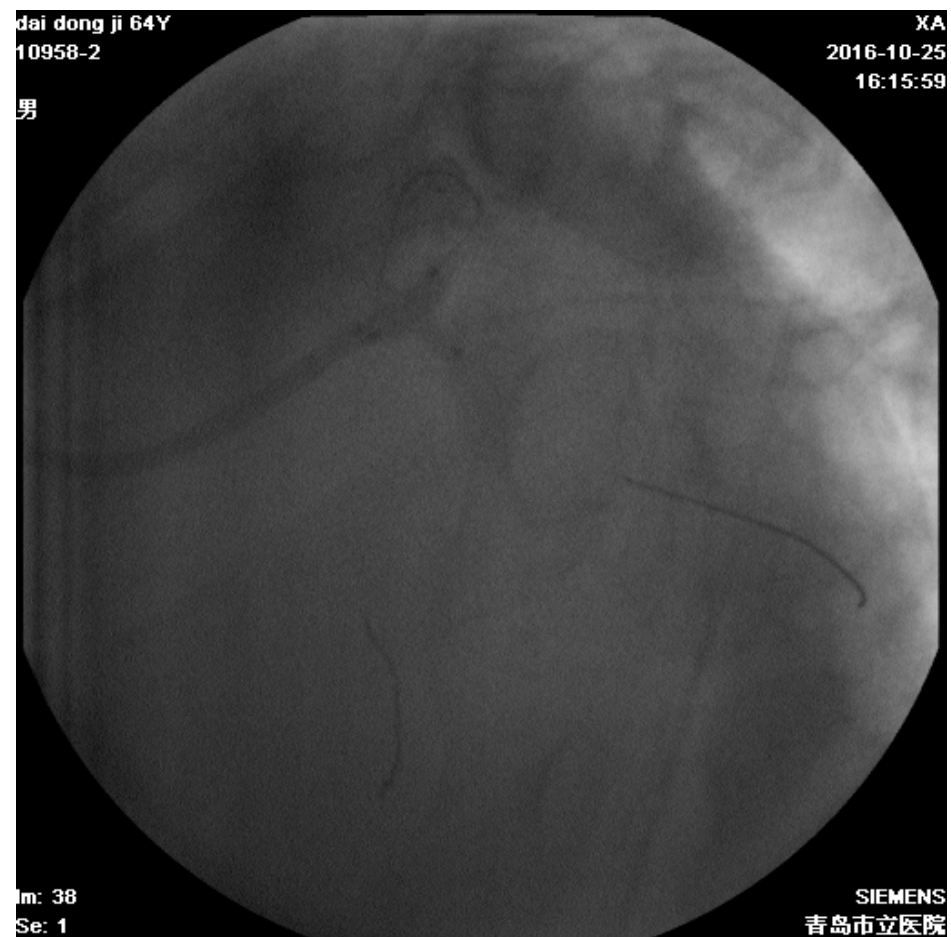


XA
2016-10-25
16:09:58

SIEMENS
青島市立医院

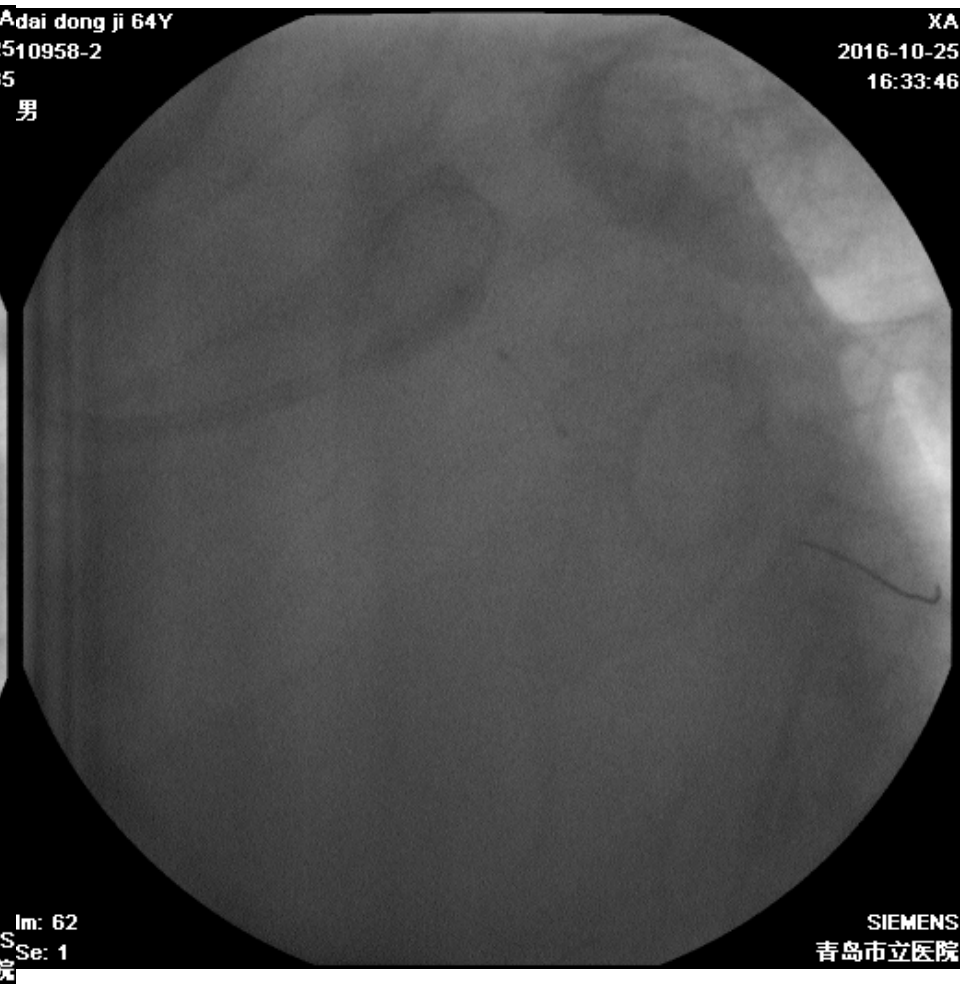
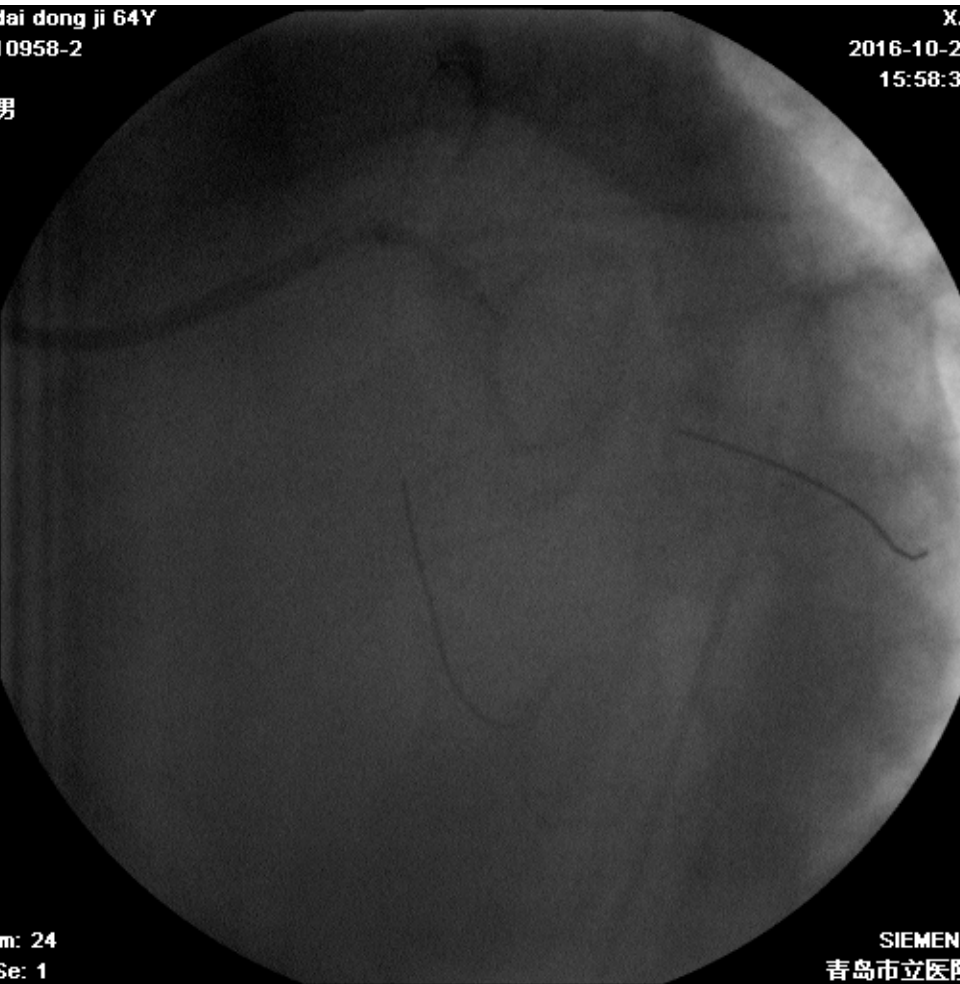
3.75*12mm NC BL/2.5*10mm
BUMA STENT 12atm

3.75*12mm NC
BL10atm*15sec Crush



First kissing:3.75*12mm NC BL
/2.5*9mm NC SPRINTER 10atm

BUMA STENT 3.5*15mm 14atm

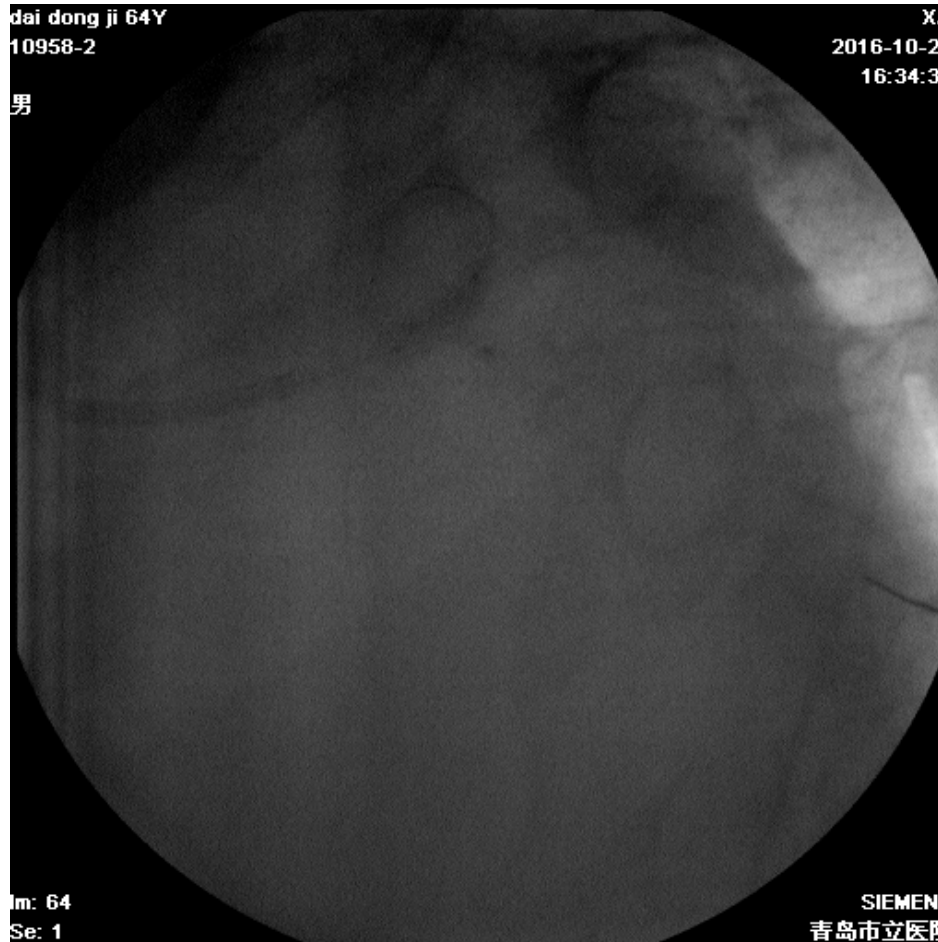


1.25*12mm SPRINTER BL /
2.5*12mm SPRINTER BL 10atm

3.75*12mm NC BL 14-16atm

dai dong ji 64Y
10958-2

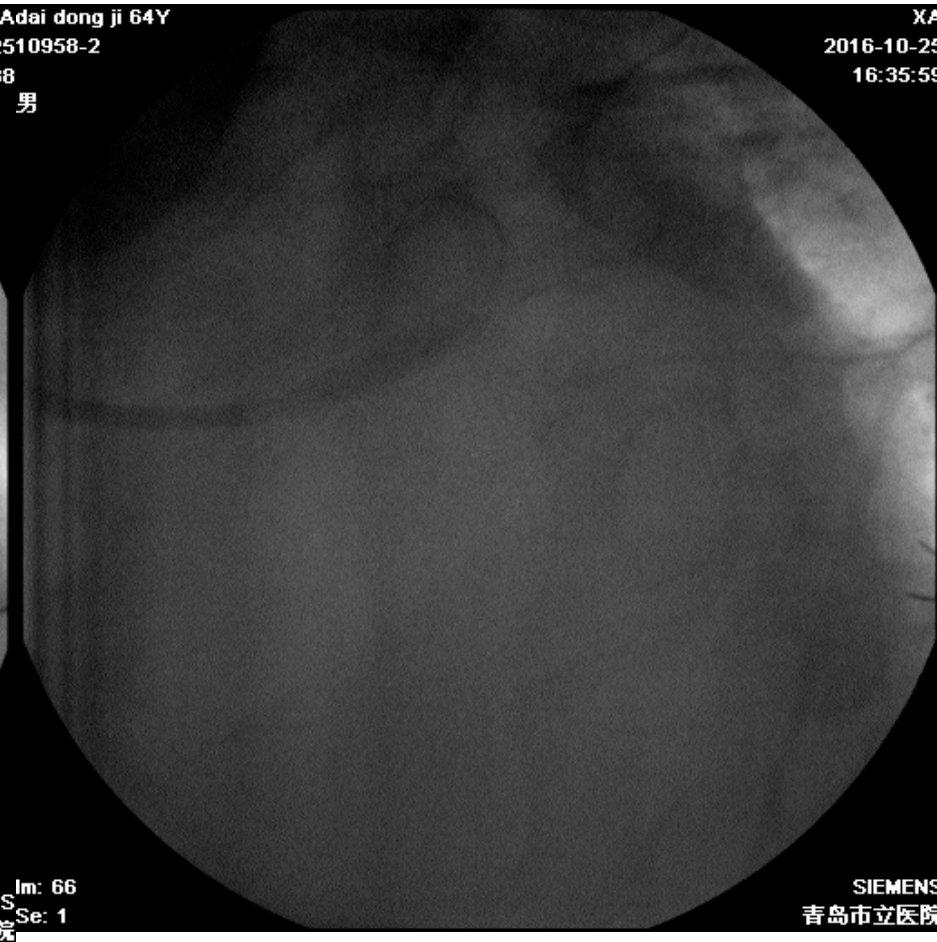
男



Im: 64
Se: 1

XAdai dong ji 64Y
2016-10-2510958-2
16:34:38

男



Im: 66
SIEMENS Se: 1
青島市立醫院

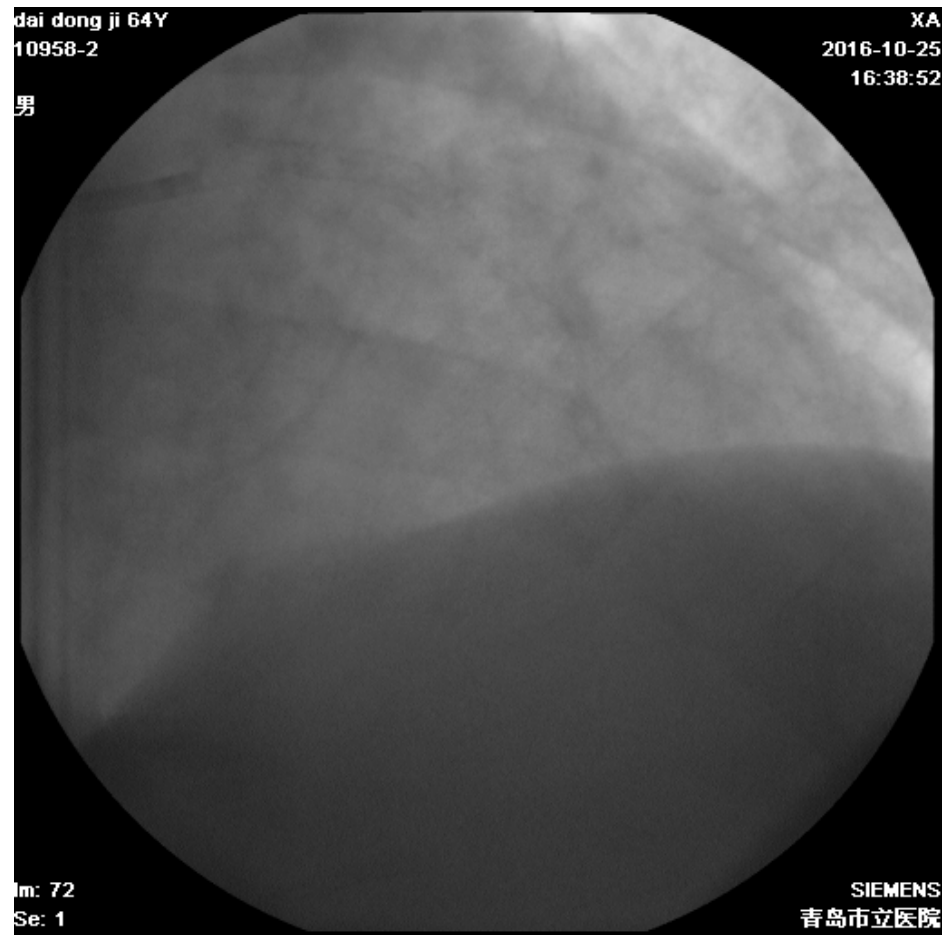
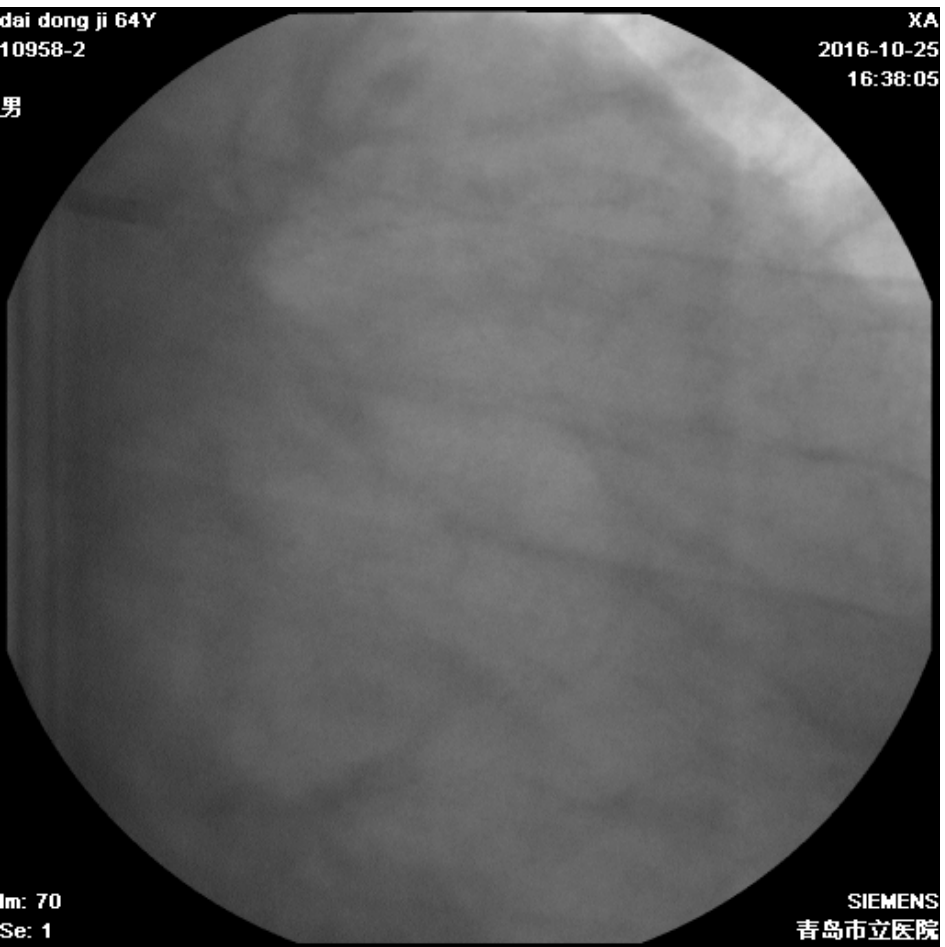
XA
2016-10-25
16:35:59

SIEMENS
青島市立醫院

Final kissing:3.75*12mm Quantum BL

POT:3.75*12mm NC BL 20atm

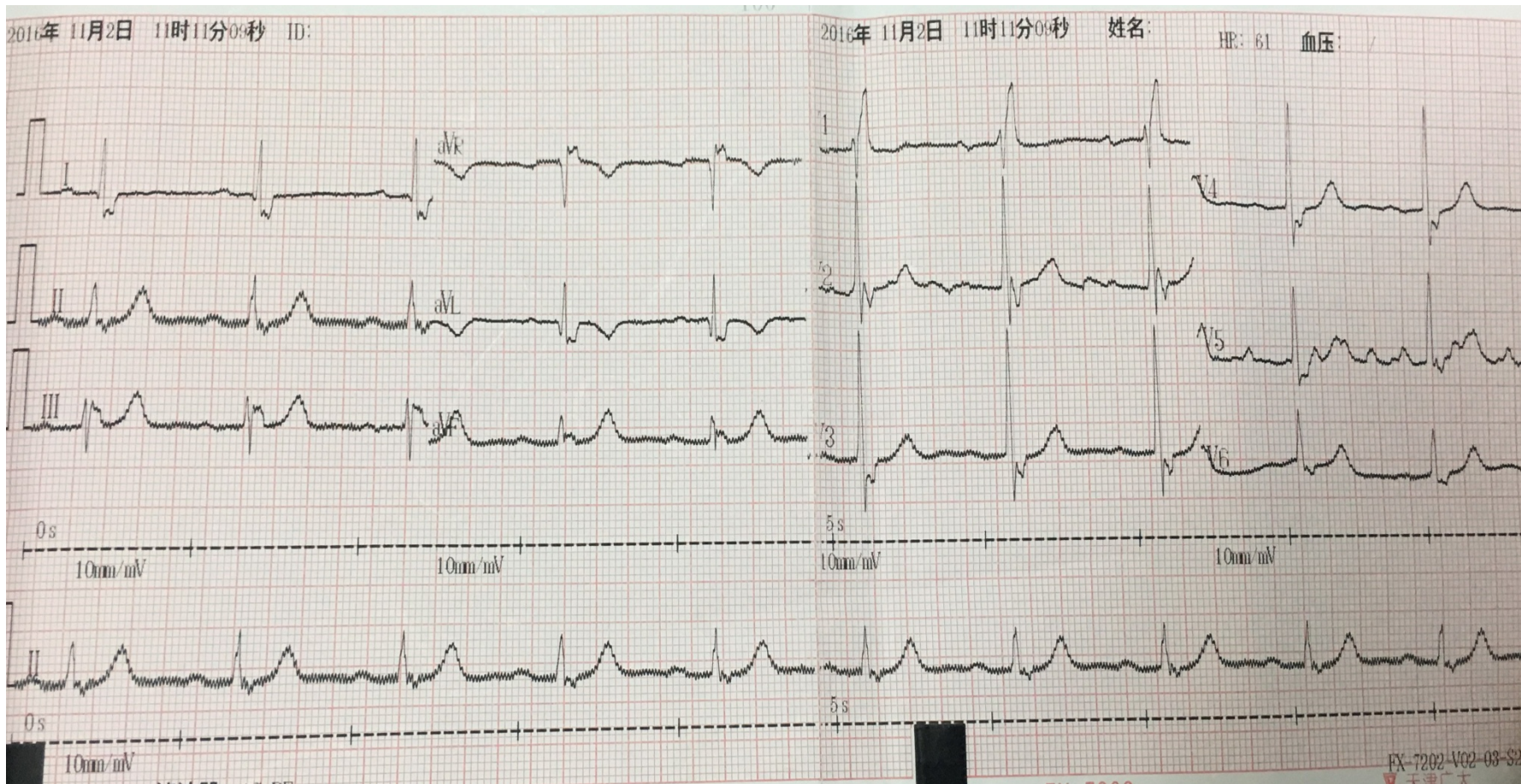
/2.5*9mm NC SPRINTER 10atm



Cases 2

- Male, 90 years old
- Complaint: Paroxysmal chest pain, chest tightness for 20 days
- Past history : diagnosed AMI by local hospital 20 days ago , DM 10 years

ECG



Echocardiogram:

二维及M超				频谱多普勒	
升主动脉	33 mm	主动脉窦	36 mm	主动脉瓣流速	1.0 m/s
主动脉瓣环	19 mm	左房前后径	33 mm	三尖瓣压差	/ mmHg
左房左右径	/ mm	左房上下径	/ mm	二尖瓣E峰	0.7 m/s
室间隔	9.2 mm	左室前后径	50 mm	二尖瓣A峰	1.0 m/s
左室后壁	8.0 mm	RVOT前后径	24 mm	DT时间	/ ms
右室左右径	32 mm	右房左右径	33 mm	二尖瓣环侧壁Em	7.5 cm/s
主肺动脉	22 mm	EF	45 %	二尖瓣环间隔Em	/ cm/s

超声描述:

床旁超声探查，声窗差，结果供参考！

心脏各房室内径正常，前室间隔厚度、回声正常，动度及增厚率略减低，余室壁厚度、回声、动度及增厚率正常。主动脉瓣为三叶瓣，局限性增厚，回声增强，开放可，关闭裂隙，余瓣膜形态、结构及启闭未见异常。

CK及STI：可探及处室壁未见明显节段性运动异常。

AQ：左室舒张末容积及每搏输出量正常范围。

Doppler：主动脉瓣见少量反流信号，二尖瓣前向血流E/A<1。

TVI：二尖瓣环运动Em=6.8cm/s，Am=7.3cm/s，Sm=6.5cm/s。

超声提示:

左室壁节段性运动减低
 主动脉瓣退变并反流（轻度）
 左心功能减低

Laboratory Examination

LDL 1.88mmol/L, CTNI < 0.05ng/ml,

BNP 432pg/ml, CR 89.78umol/L

Diagnosis

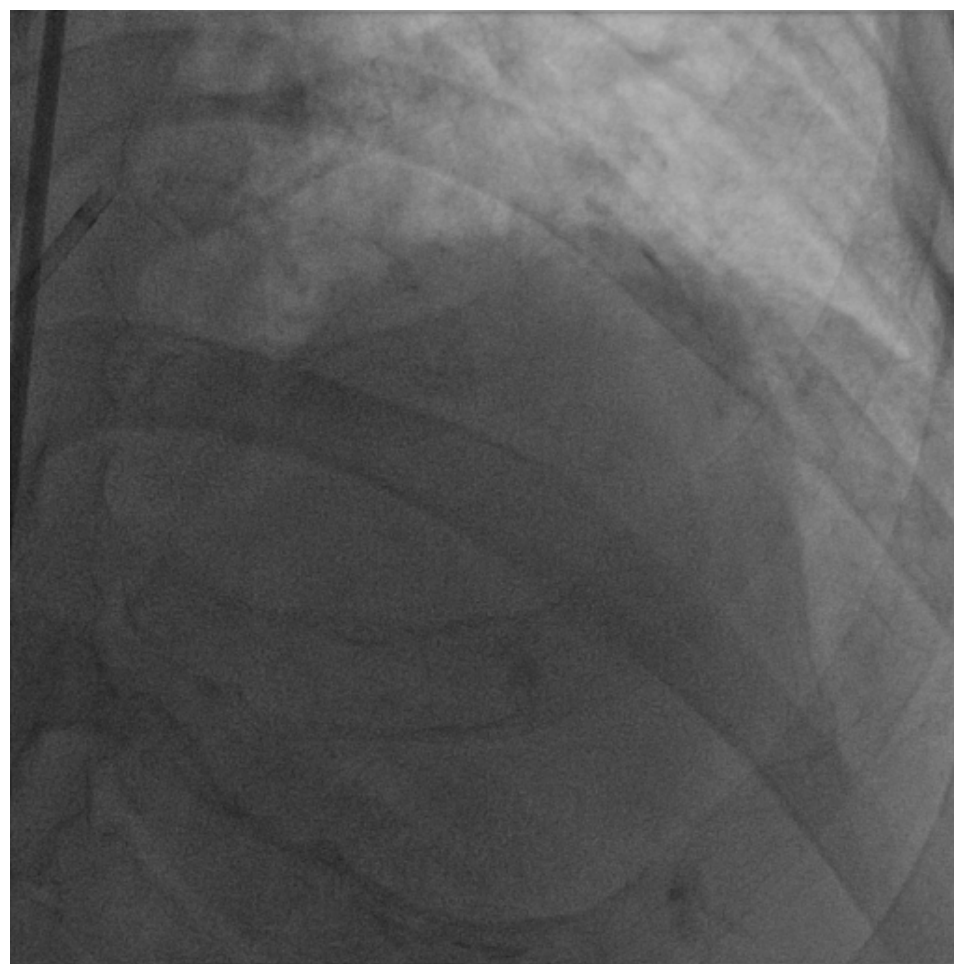
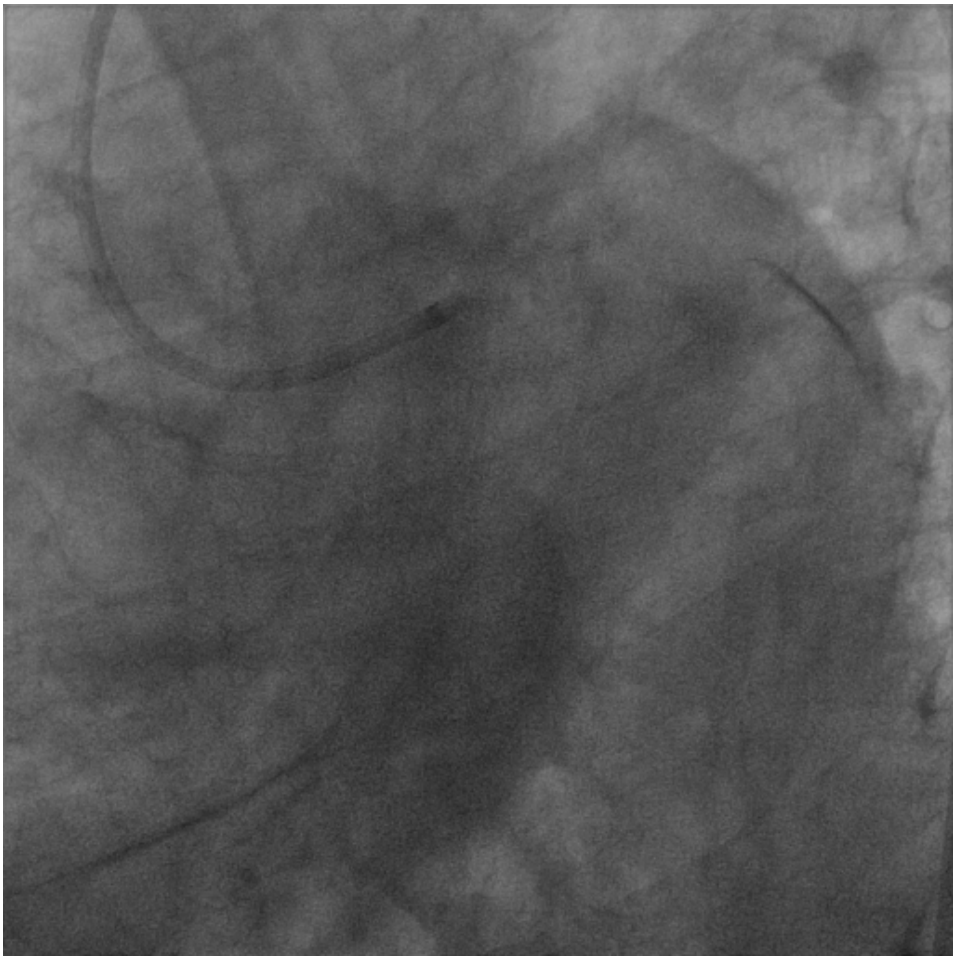
1. CHD

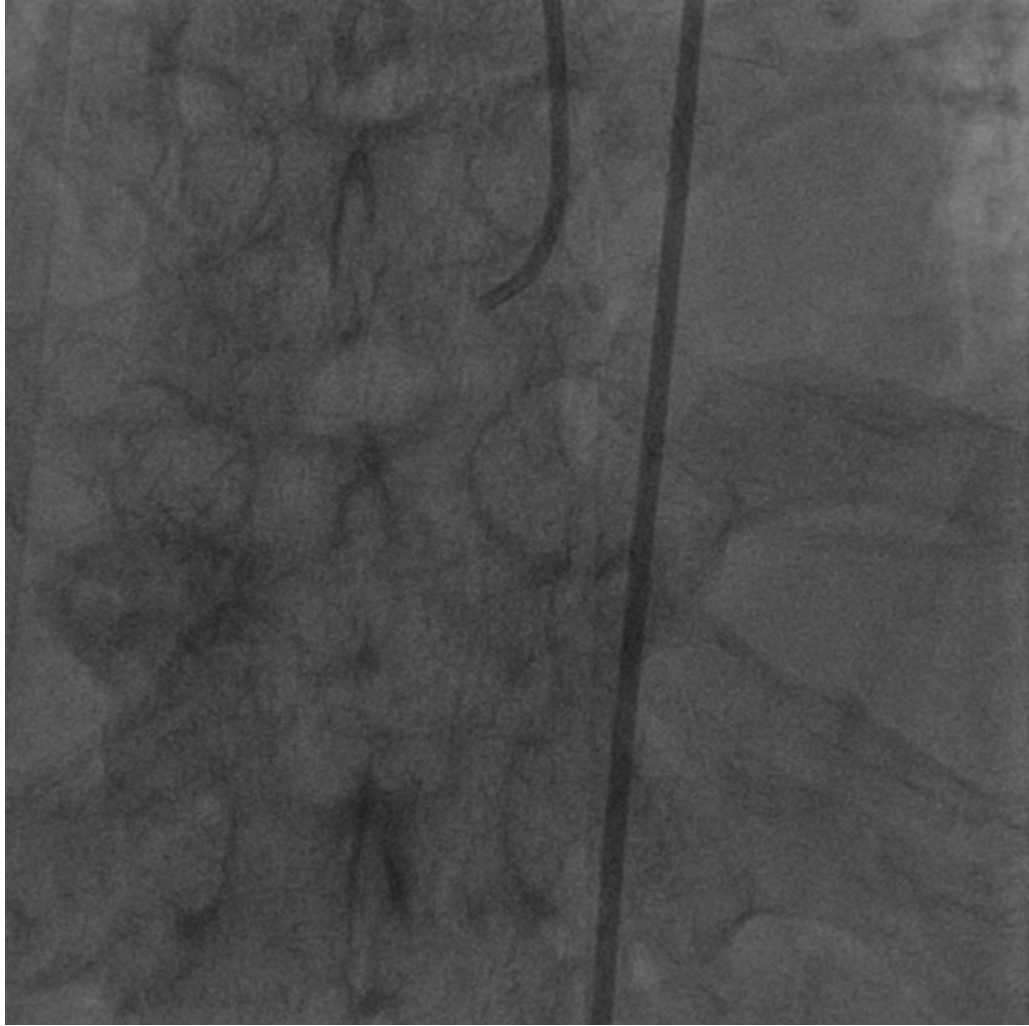AMI

Cardiac function Grade I (Killips)

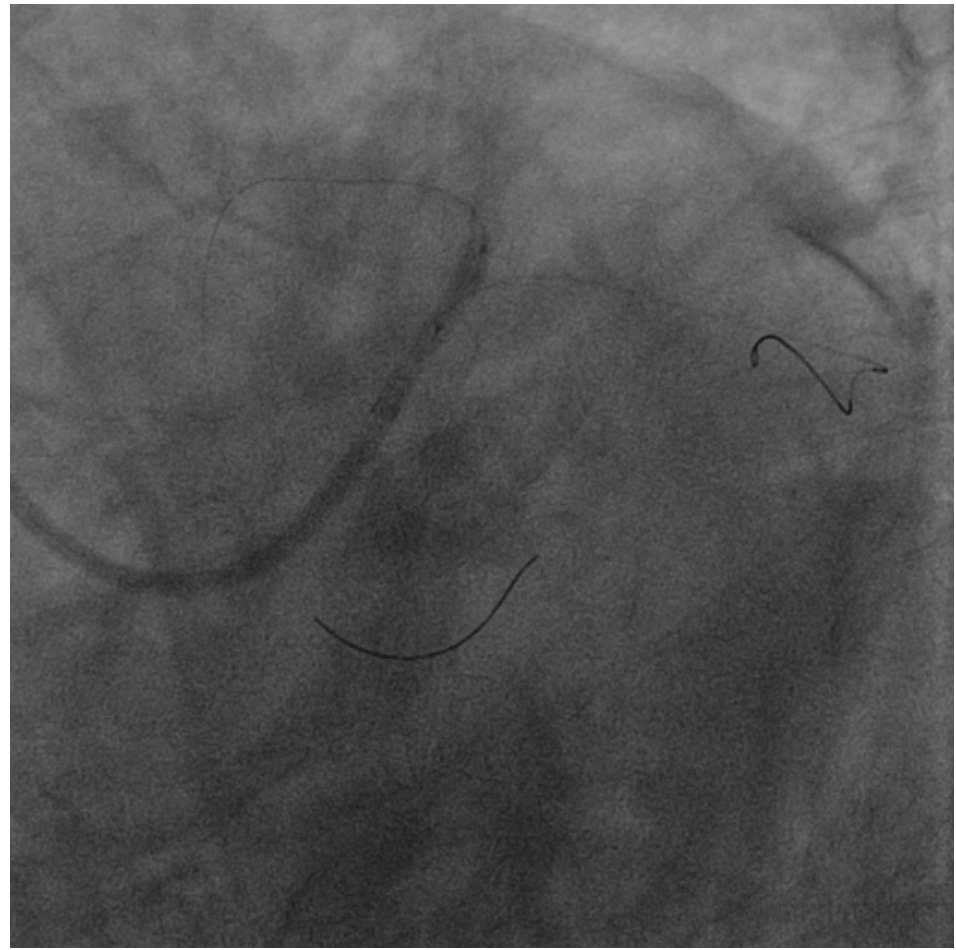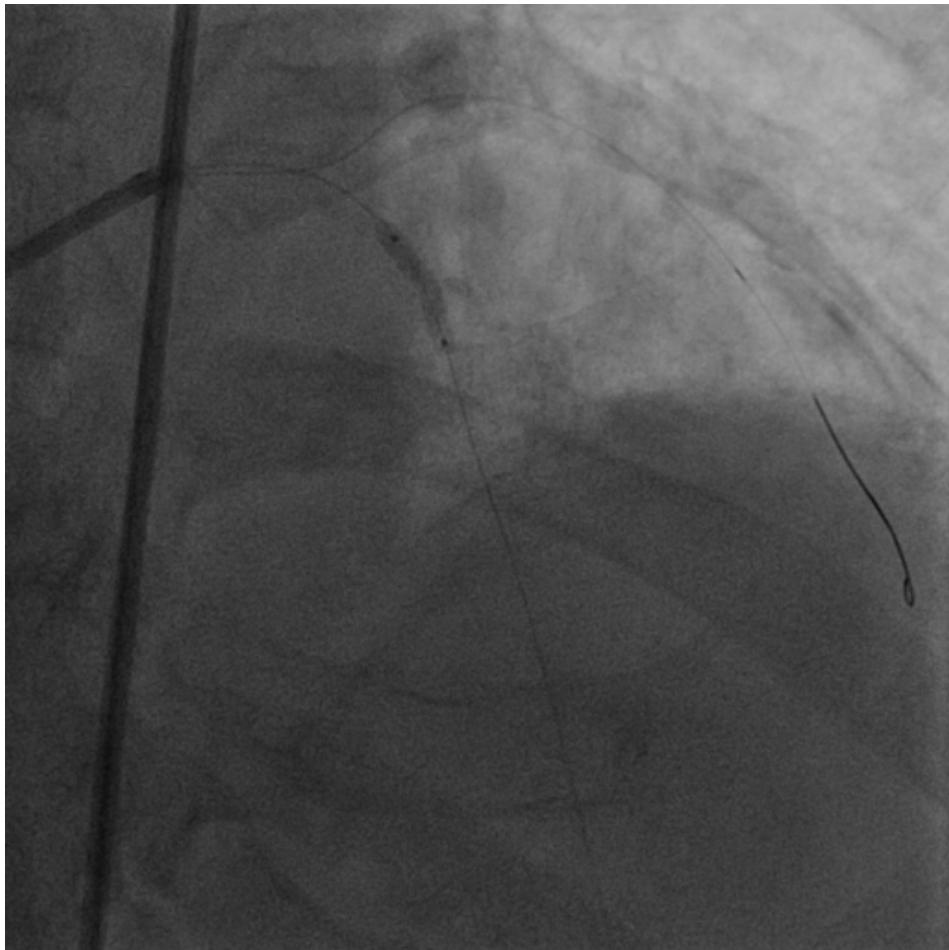
2. Type-2 diabetes

CAG

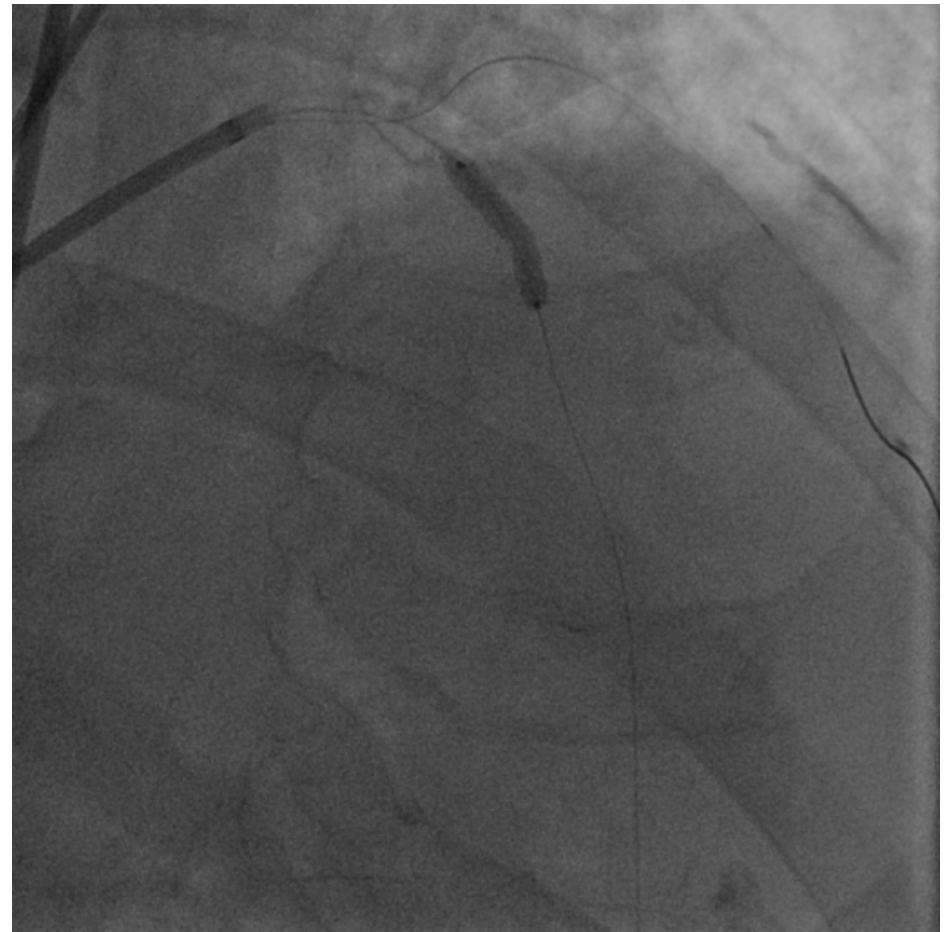
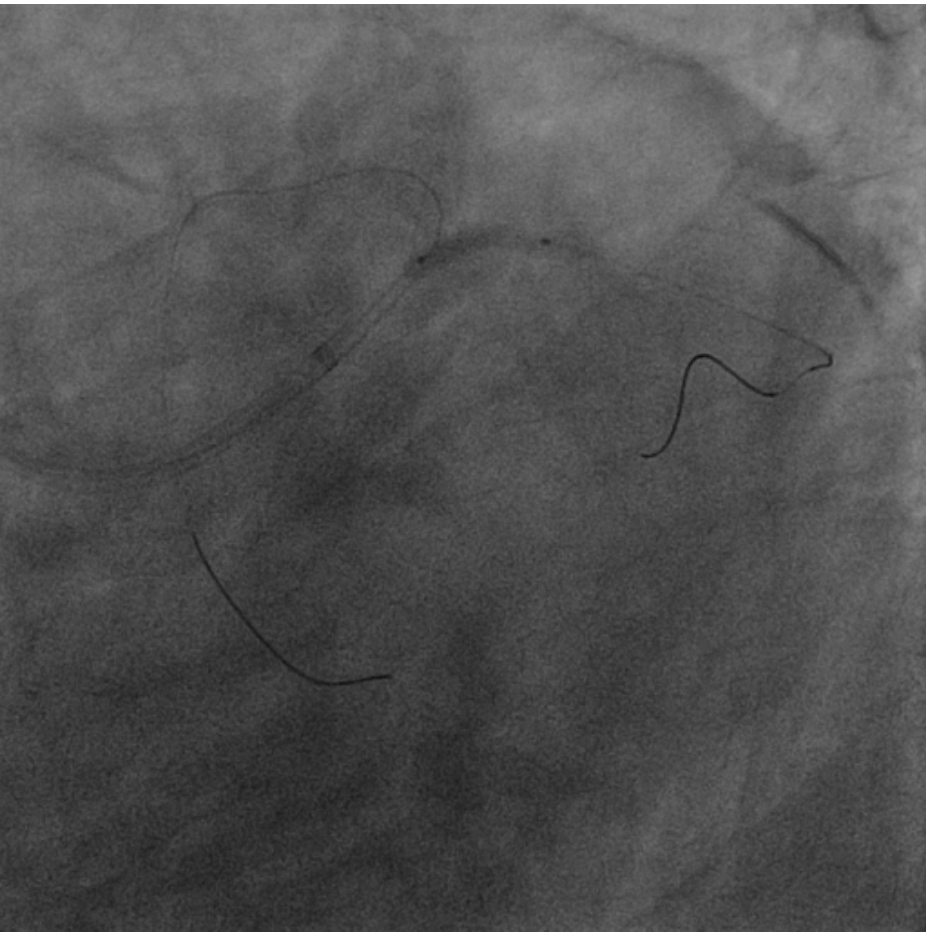


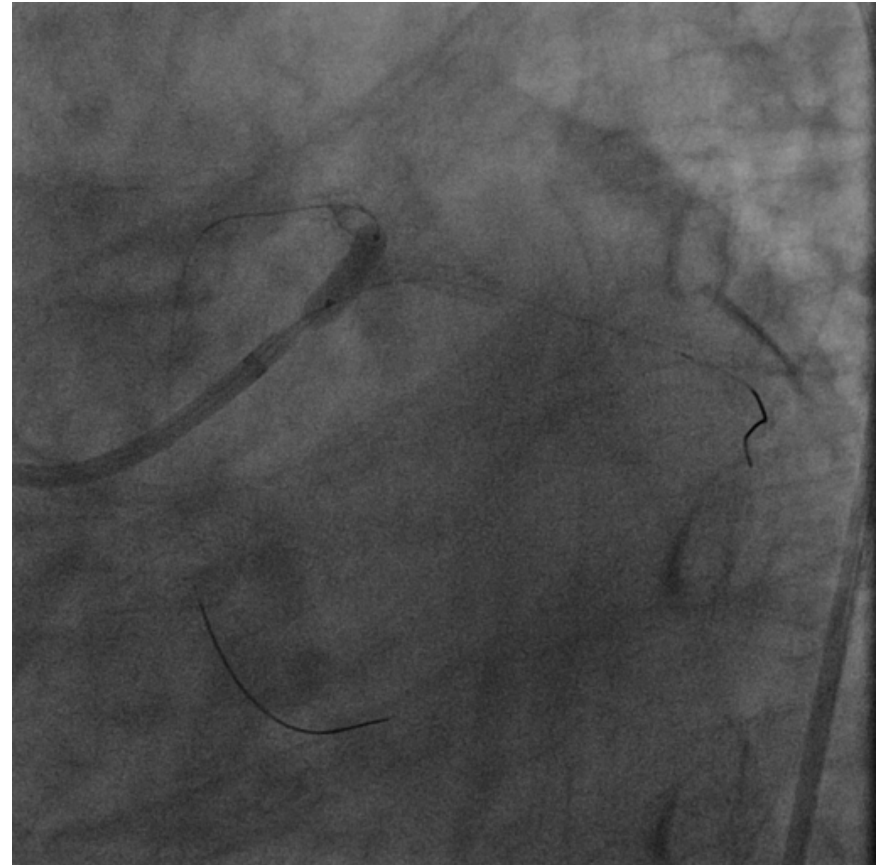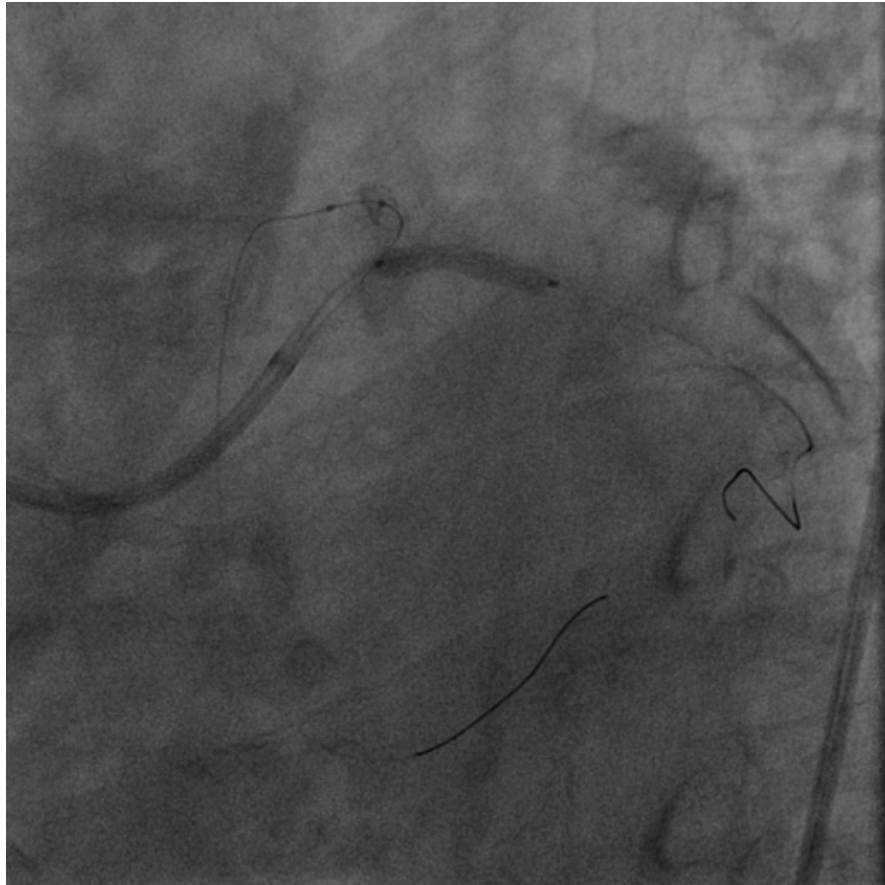DK-CRUSH



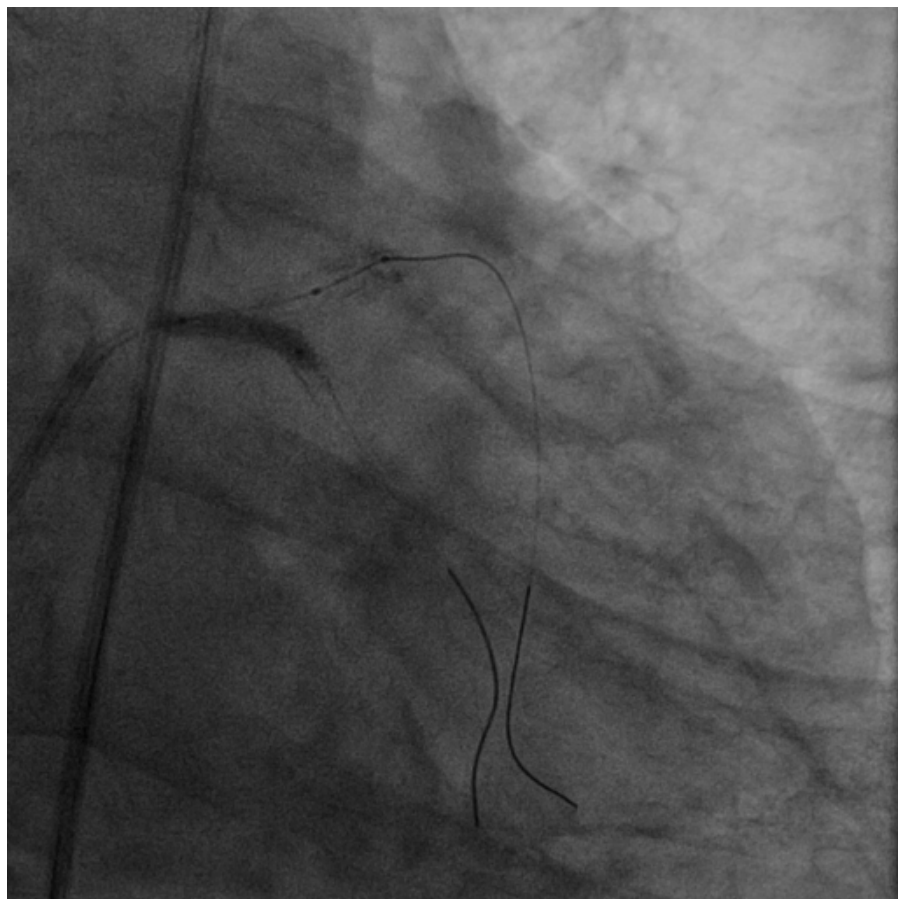
7F EBU37.5 GC/Runthrough GW /BMW GW/ 2.5*15mm SPRINTER BL



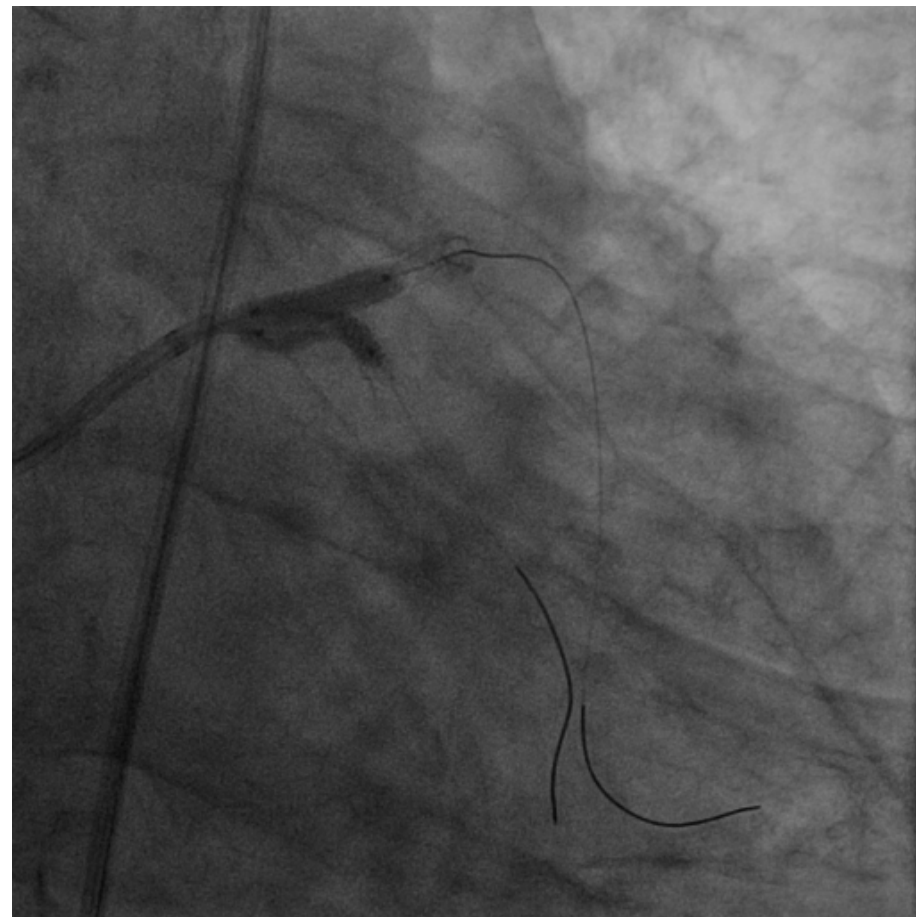
2.75*18mm Resolute STENT 14atm



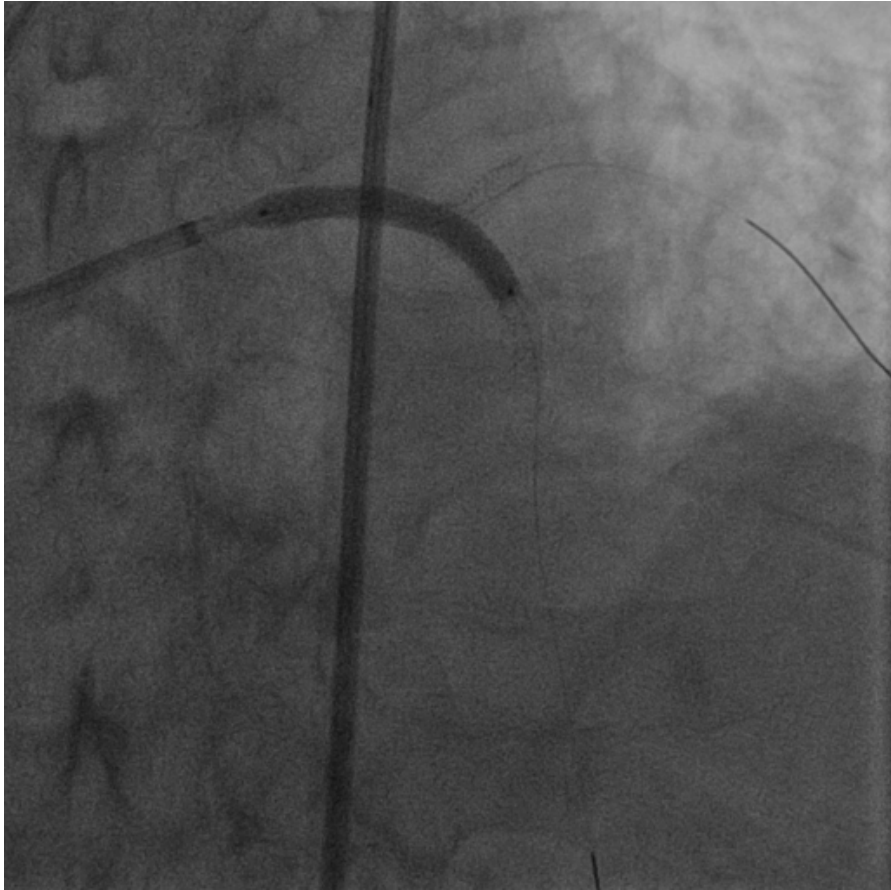
4.0*15mm NC SPRINTER BL/3.0*18mm Resolute STENT
14atm



1.25*15mm SPRINTER /2.5*15mm
SPRINTER

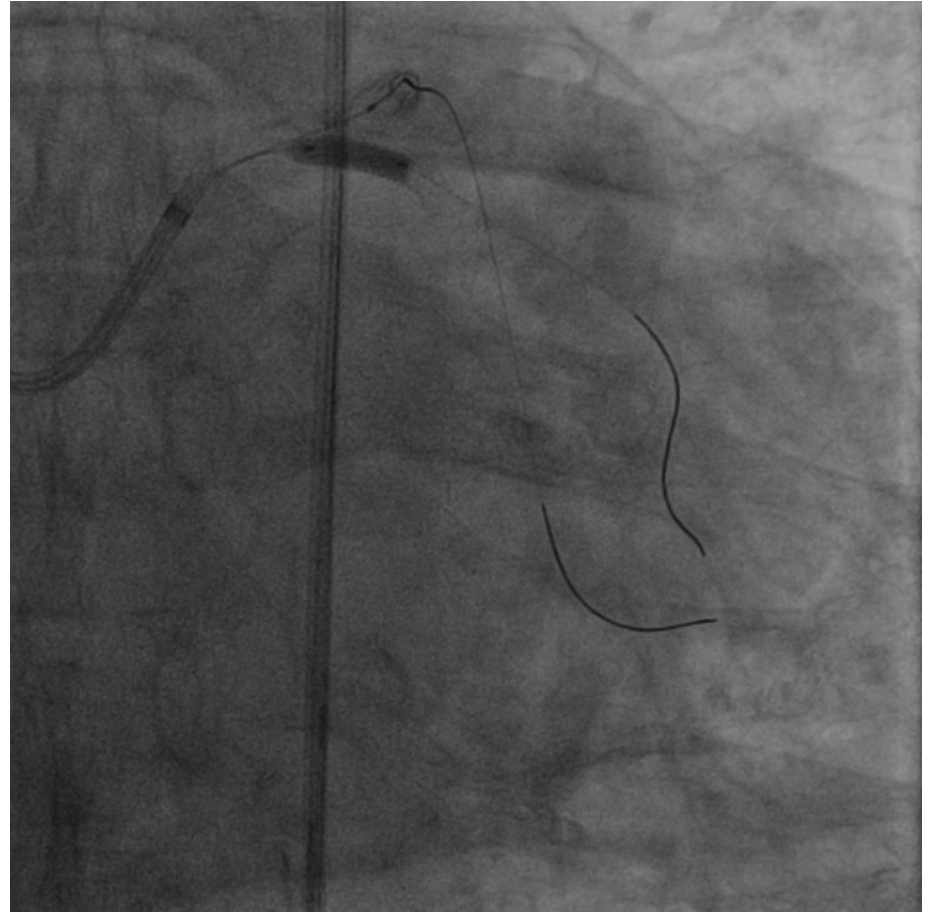


First kissing: 4.0*15mm NC SPRINTER
BL/ 3.25*12mm NC SPRINTER



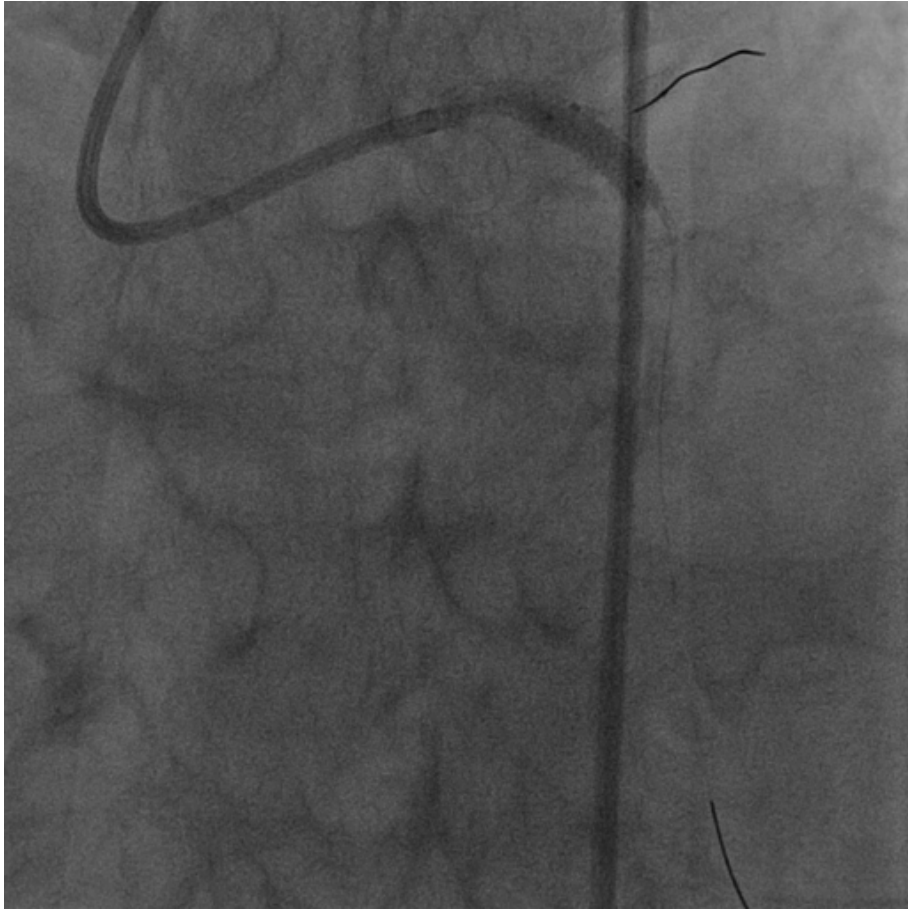
4.0*30mm

Resolute 14atm

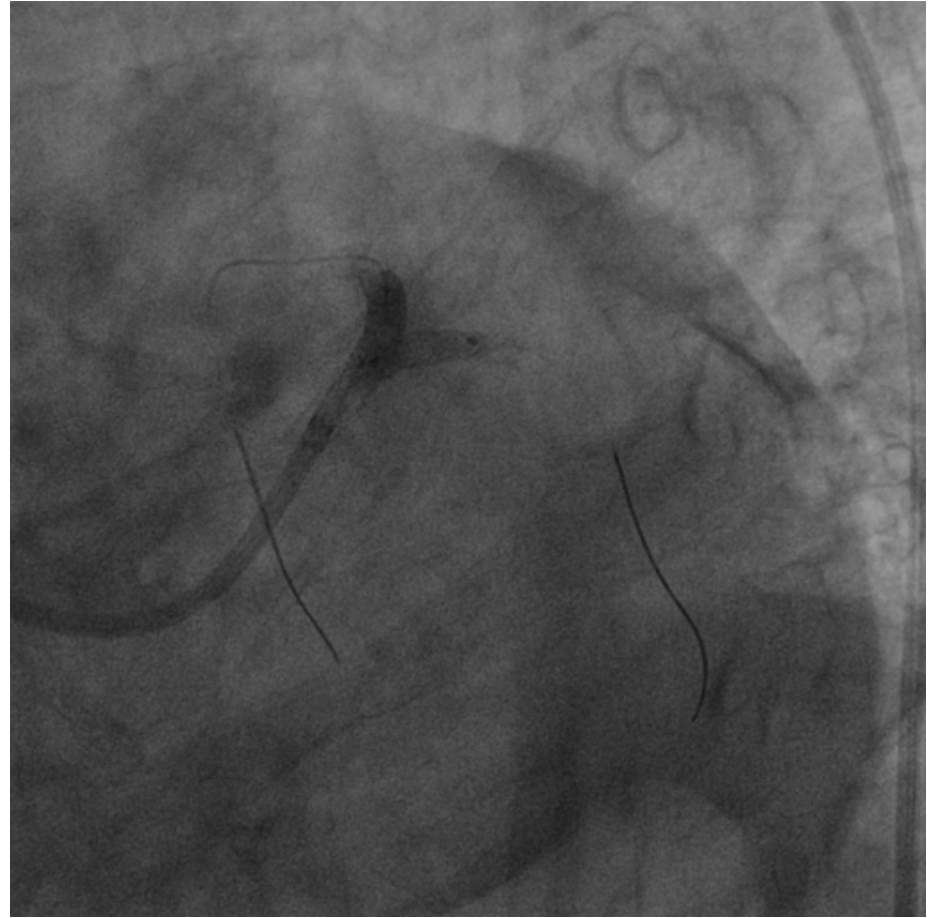


2.5*15mm SPRINTER BL /

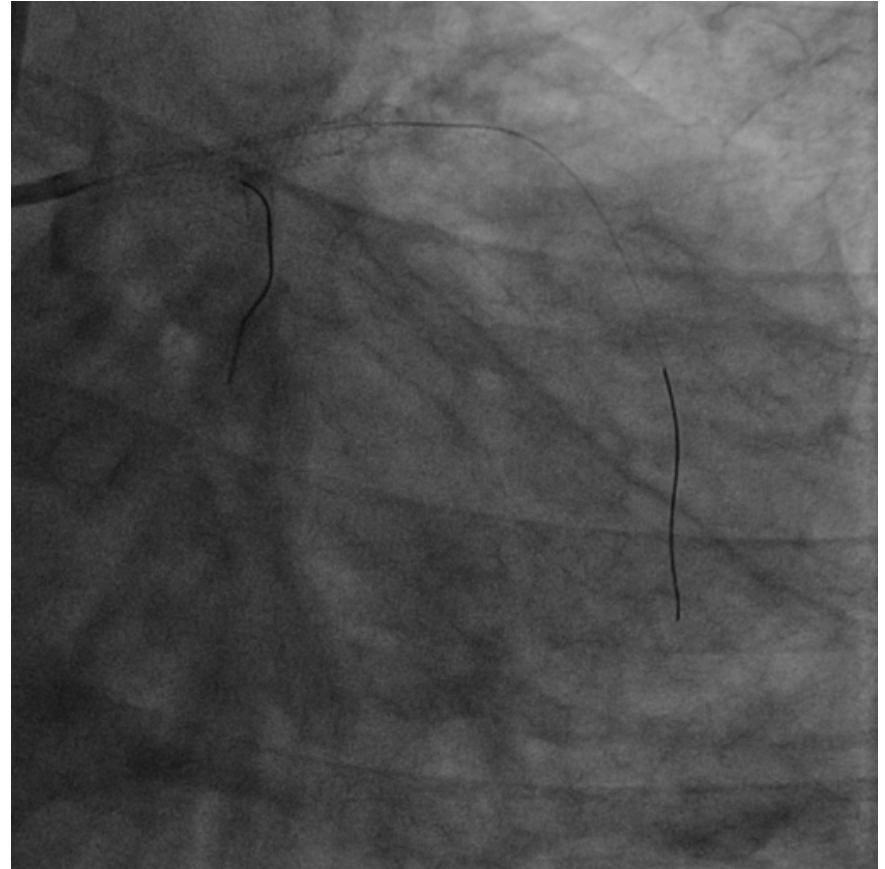
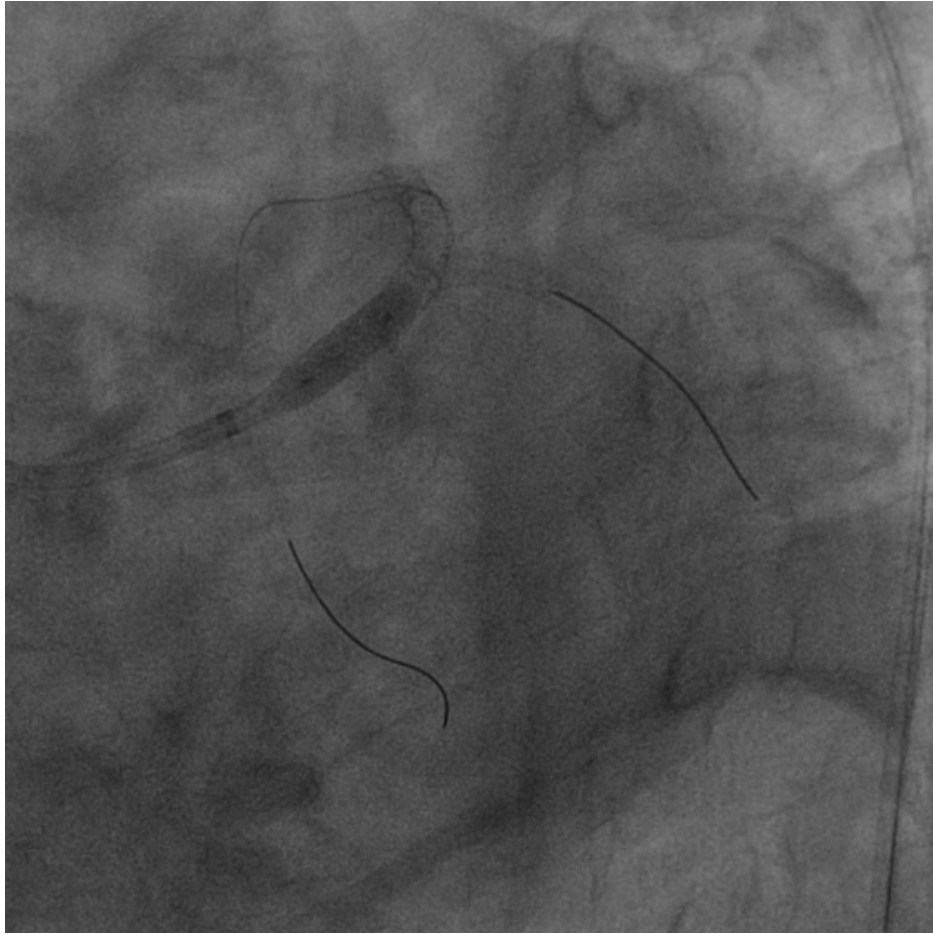
3.25*12mm NC SPRINTER BL



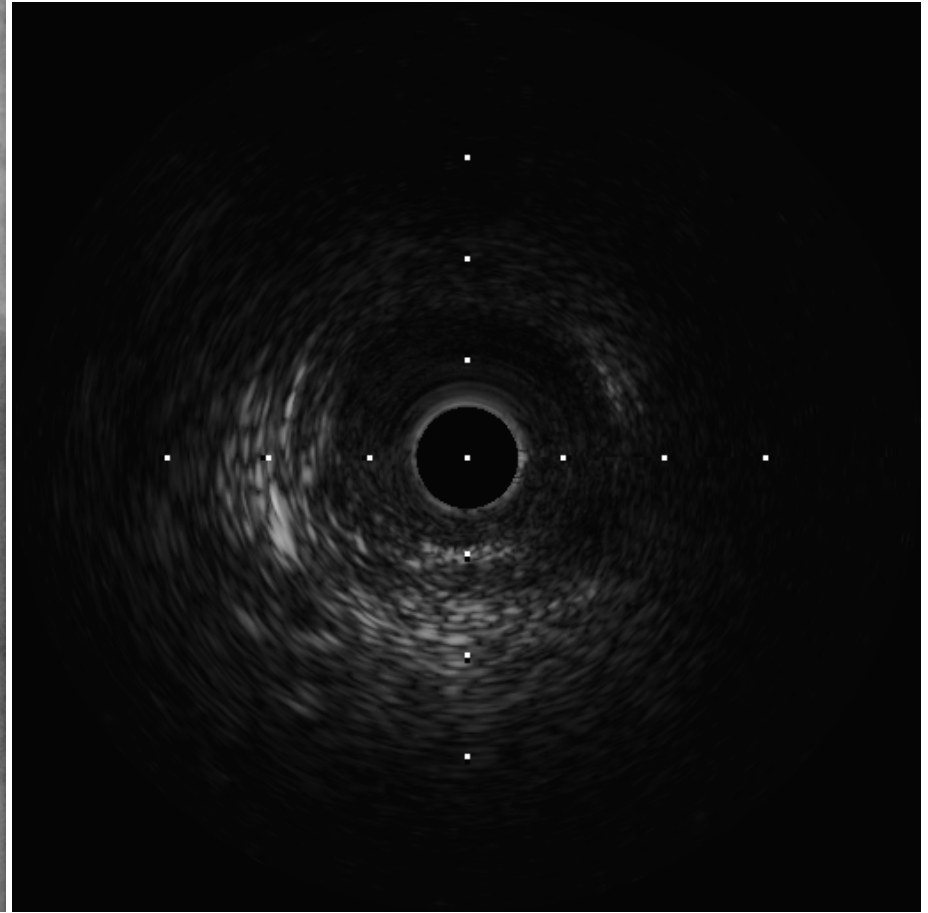
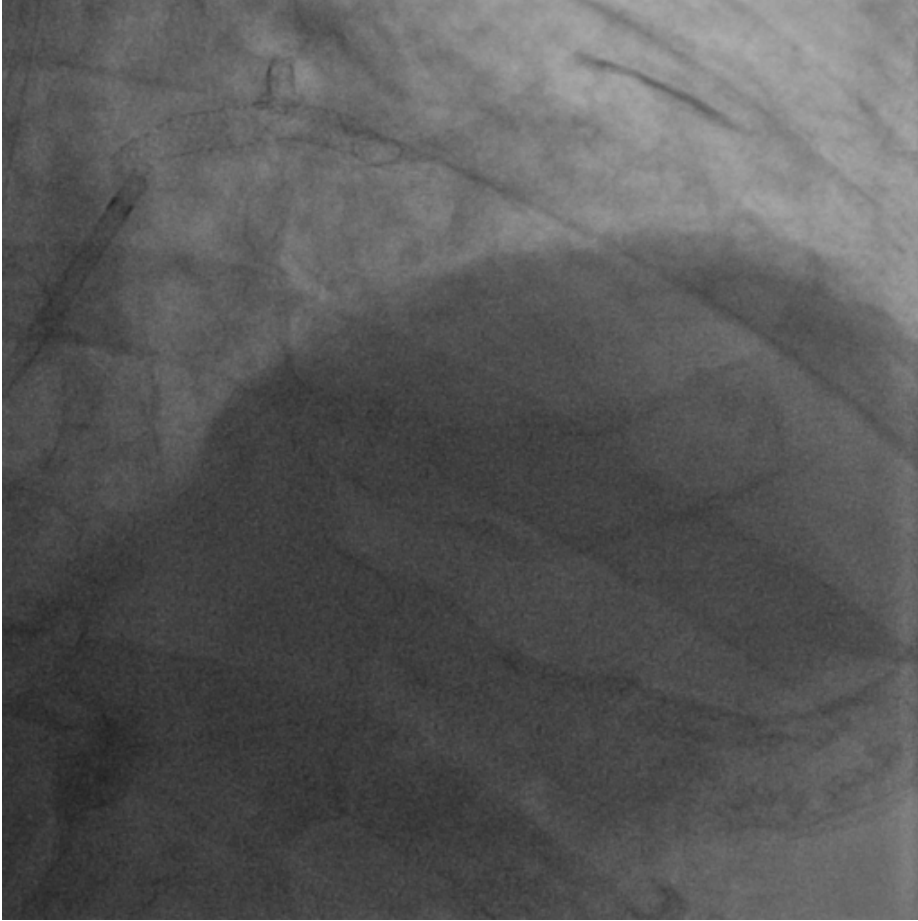4.0*15mm NC SPRINTER BL



Final kissing: 4.0*15mm NC SPRINTER
BL/ 3.25*12mm NC SPRINTER BL
10atm



POT:4.5*12mm NC BL 20atm



LAD-LM:IVUS

Thank you very much!
感谢您的聆听!



青島市市立醫院(集團)
QINGDAO MUNICIPAL HOSPITAL (GROUP)

生命綠洲
王訓頌敬書

